

CASE REPORT

DOI: <https://doi.org/10.18502/fem.v6i3.9403>

Cutaneous vasculitis following COVID-19 vaccination: a case-based review

Rama Bozorgmehr¹, Katayoun Enteshari^{2*}, Arash Khameneh Bagheri³, Reza Jafarzadeh Esfehiani⁴, Fahimeh Abdollahimajd⁵

1. Department of Pulmonology, Clinical Research Development Unit, Shohada-e Tajrish Hospital, Shahid Beheshti University of Medical Sciences, Tehran, Iran.
2. Department of Rheumatology, Shohada-e Tajrish Hospital, Shahid Beheshti University of Medical Sciences, Tehran, Iran.
3. Department of Radiology, Shohada-e Tajrish Hospital, Shahid Beheshti University of Medical Sciences, Tehran, Iran.
4. Blood Borne Infections Research Center, Academic Center for Education, Culture and Research (ACECR)- Khorasan Razavi, Mashhad, Iran.
5. Clinical Research Development Unit, Shohada-e Tajrish Hospital, Shahid Beheshti University of Medical Sciences, Tehran, Iran.

*Corresponding Author: Katayoun Enteshari; Email: k.enteshari@sbmu.ac.ir

Published online: 2022-03-05

Cite this article as: Bozorgmehr R, Enteshari K, Khameneh Bagheri A, Jafarzadeh Esfehiani R, Abdollahimajd F. Cutaneous vasculitis following COVID-19 vaccination: a case-based review. *Front Emerg Med.* 2022;6(3):e41.

1. Introduction

Although most of the patients who get infected with severe acute respiratory syndrome coronavirus 2 (SARS-CoV-2) develop respiratory symptoms similar to an upper respiratory tract infection, complications in body organs other than the respiratory system are far from exception (1-3). Vasculitis is a rare complication of COVID-19, resulting in a poor prognosis if left untreated (4, 5). Since there is no specific curative treatment available for COVID-19 and its complications, preventive strategies such as vaccination are considered the only effective way of controlling the pandemic. Although the available COVID-19 vaccines are considered safe with minimal adverse reactions, vaccination may have rare and even lethal adverse effects in some individuals. Overall, it has been reported that the most common side effects of COVID-19 vaccines are local reactions at the injection site and the dermatologic side effects vary from morbidiform rashes to erythema multiforme and pityriasis rosea (6-8). A growing number of reports suggest vasculitis as a complication of COVID-19 vaccines in different populations, including those with underlying chronic liver or dermatologic diseases (9-12). The following report discusses the lethal outcome of a vasculitis case following COVID-19 mRNA vaccination in a female patient with underlying SARS-CoV-2 infection.

2. Case presentation

A 56-year-old female presented to the emergency department (ED) due to dizziness, hematemesis, absence of urination, and purpura over her limbs and abdomen. The symptoms had started the day before, and her clinical condition was getting worse. Her previous medical history included controlled hypertension and hypothyroidism since three years ago. The patient was receiving levothyroxine, losartan, diltiazem, rosuvastatin, and aspirin. Despite receiving

her first dose of Astrazeneca vaccine 30 days ago, she had developed COVID-19 symptoms including cough, myalgia, and fatigue 20 days after vaccination. She had tested positive for SARS-CoV-2 infection and received daily acetaminophen, famotidine, and favipiravir. She had developed progressive skin manifestations the day after the initiation of symptoms, including urticarial and purpuric lesions over her upper and lower extremities and abdomen (Figure 1), but plantar surfaces were spared. There was no mucosal involvement. Gradually, she had become anuric, developed nausea, vomiting, and hematemesis just before referring to the ED.

At the time of admission, the patient was ill and cyanotic. Her vital signs were as follows: blood pressure: 80/60 mmHg; pulse rate: 110 pulse/minute; respiratory rate: 28 breath/minute; axillary temperature: 37 °C and SpO₂: 87% at room air. Due to her unstable clinical condition and central cyanosis, the patient was transferred to the intensive care unit (ICU) and received supplementary oxygenation. The initial laboratory tests revealed markedly elevated serum creatinine (3.34 mg/dl), urea (56 mg/dl), alanine aminotransferase (4600 U/L), aspartate aminotransferase (2900 U/L), lactate dehydrogenase (18230 U/L), alkaline phosphatase (237 IU/L), and d-dimer (5000 ng/mL) as well as leukocytosis (16400 white blood cell (WBC) per mm³). While the patient was anuric, a urine specimen was taken after catheterization revealing microscopic and gross hematuria. polymerase chain reaction (PCR) test confirmed SARS-CoV-2 infection, and computed tomography pulmonary angiography (CTPA) revealed consolidations compatible with the diagnosis of COVID-19 without any sign of thromboembolism (Figure 2). Also, the patient had positive hepatitis B antigen and positive HBe Ab, prolonged prothrombin time (22.6 seconds) and partial thromboplastin time (117 seconds), and elevated international normalized ratio (2.1). Serum Procalcitonin level was very high; therefore, septic shock was one of the dif-

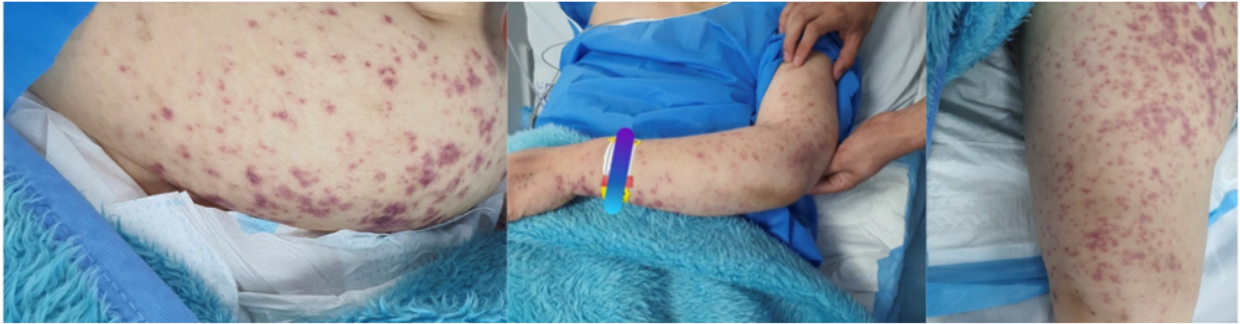


Figure 1 The figure shows the urticarial and purpuric lesions on the abdomen, and upper and lower extremities

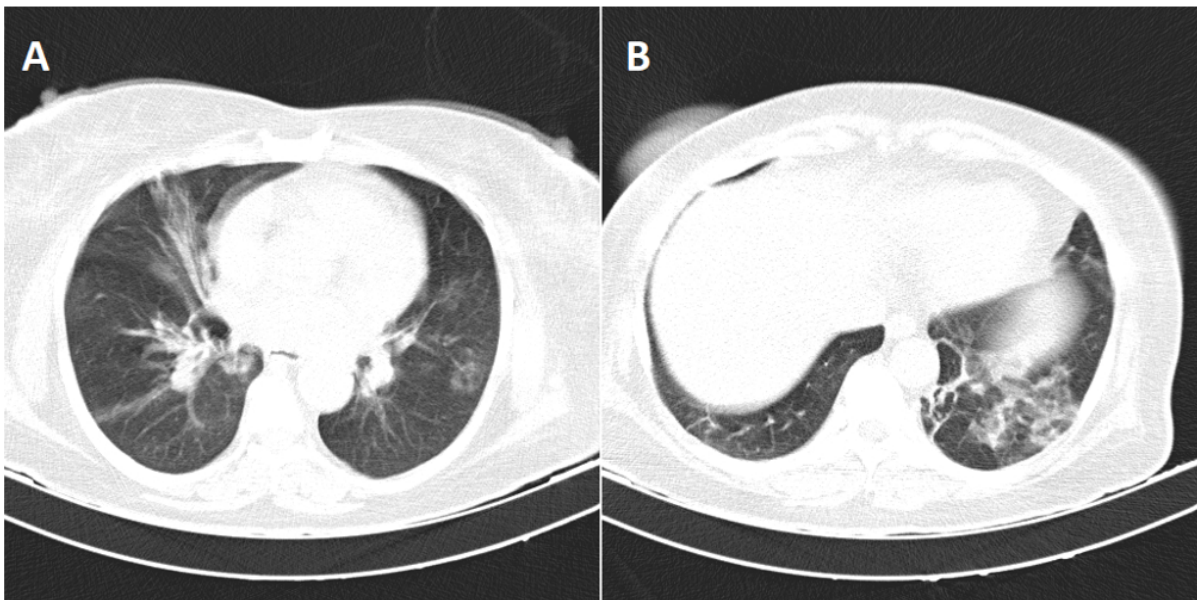


Figure 2 Thoracic computed tomography of lung window shows multifocal and diffuse ground glass patches over both lung fields resembling COVID-19 infection (A). The reticular and “tree in buds” sign and mosaic pattern in the left lower lobe of lungs suggests superinfection (B)

ferential diagnoses.

Norepinephrine, meropenem, vancomycin, ciprofloxacin, remdesivir, and a corticosteroid pulse started during ICU admission. The patient underwent urgent dialysis due to decreasing level of consciousness, absence of urine output, and gradual increase in creatinine level during ICU admission. After a course of dialysis, the clinical condition became more stable, and the patient regained consciousness. Due to suspicion to vasculitis syndromes, a vasculitis panel was ordered (Table 1). The panel revealed that the patient had normal serum levels of P- and C-ANCA, SSA-Ro, SSB-La, anti-CCP, and increased APTT-LA, RUSSEL (DRVVT), anti-beta-2 microglobulin, and cryoglobuline, as well as decreased complements. Also, Histopathological evaluation of the skin biopsy was compatible with cutaneous small vessel vasculitis (Figure 3).

Due to progressive dyspnea, transthoracic echocardiography was performed, which demonstrated normal pulmonary artery pressure and ejection fraction. A plasmapheresis session was ordered with the possible impression of polyarteritis

nodosa based on her viral hepatitis, skin lesions, and laboratory findings. However, the clinical condition of the patient worsened, and dyspnea developed. During the sixth day of admission, the patient was intubated due to respiratory distress and decreased level of consciousness. Brain magnetic resonance imaging was ordered on the third day of intubation, and multiple brain infarcts were documented (Figure 4). The patient developed cardiac arrest on the same day and expired.

3. Discussion

The present report described a case of vasculitis following the COVID-19 vaccine in a female patient with SARS-CoV-2 infection. However, we cannot exclude the possible effect of underlying hepatitis and COVID-19 in the development of vasculitis. Therefore, we cannot differentiate the underlying cause of vasculitis in our patient, and hepatitis or SARS-CoV-2 infection. Yet, vaccines could be considered a predisposing factor for vasculitis and should be used with caution in patients with previous hepatitis.

Table 1 The serum level of biochemical and immunological markers

Marker	Result	Reference range	Method
Rheumatoid factor	<20 IU/mL	Negative: <20	Imm.Turbid
HBs Antigen	1.30 S/Co	Reactive: > 1	CLIA
Anti HCV	0.07 COI	Non-reactive: < 1	ECL
HBe Antibody	Positive	-	Qualitative
Cryoglobulin	Positive	-	Qualitative
Cardiolipin (IgG)	0.12 U/mL	Negative: < 10	CLIA
Cardiolipin (IgM)	1.4 U/mL	Negative: < 10	CLIA
pANCA	0.26 U/mL	Negative: < 12	ELISA
cANCA	0.14 U/mL	Negative: < 12	ELISA
Anti-ds DNA	3.06 U/mL	Negative: < 16	ELISA
C3	0.57 g/l	0.89-1.87	Imm.Turbid
C4	0.17 g/l	0.1-0.4	Imm.Turbid
CH50	32.21 U/mL	41.2-95.0	Imm.Turbid
FANA	Negative	Negative: < 100	IF
Anti-phospholipid (IgG)	0.13 U/mL	Normal: < 12	ELISA
Anti-phospholipid (IgM)	0.82 U/mL	Normal: < 12	ELISA
Beta 2 Microglobulin	21.12 mg/L	0.81-2.19	ELFA
LDH	18230 U/L	135-214	IFCC
Free Kappa	126.1 mg/L	3.30-19.40	Imm.Turbid
Free Lambda	166.6 mg/L	5.71-26.30	Imm.Turbid
Serum Total Protein	5.3 g/dL	6.6-8.70	Colorimetric
RUSSEL (DRVVT)	111.2	30-38	-
APTT-LA	70.2 sec	32-46	-
Anti CCP	1.9 EU/ml	Negative: < 30.0	ELISA

HBs: hepatitis B surface; HCV: hepatitis C virus; HBe: hepatitis B envelope; p-ANCA: perinuclear anti-neutrophil cytoplasmic antibodies; c-ANCA: centrally accentuated anti-neutrophil cytoplasmic antibodies; FANA: fluorescent antinuclear antibody; LDH: lactate dehydrogenase; DRVVT: dilute Russell's viper venom time; APTT-LA: activated partial thromboplastin clotting time- lupus anticoagulant; CCP: cyclic citrullinated peptide.

Although the exact mechanism of vasculitis following SARS-CoV-2 infection is not clearly understood, it seems that a similar pathological mechanism could be responsible for the development of vasculitis following COVID-19 vaccination with vaccines. It has been reported that patients with non-HCV-related infectious mixed cryoglobulinemic vasculitis usually have a poor prognosis and the prognosis mainly depends on the underlying infection and initiation of corticosteroids. Postmortem studies on COVID-19 patients demonstrated that during severe infection, immune-thrombotic clots could be found in respiratory tissue suggesting direct embolization. It has been demonstrated that COVID-19 patients are at higher risk of developing cryptogenic stroke than the general population, which is usually associated with increased D-dimer concentration, reflecting diffuse pulmonary intravascular coagulopathy (7). It has been previously reported that diffuse cutaneous lesions may be associated with extensive small ischemic lesions in brain imaging studies suggesting cerebral vasculitis similar to our patient. On the other hand, a recent clinicopathological study on the brain tissue of COVID-19 patients revealed deep parenchymal ischemic infarcts and did not demonstrate evidence of vasculitis (13). Similar to our patient, evidence of vasculitis outside the cutaneous and central nervous system has been reported in the literature (7). A growing number of cases are suggesting

vasculitis due to COVID-19, but the exact underlying mechanism is not yet clearly understood. Antigen excess during SARS-CoV-2 infection induces the formation of antigen and antibody complexes resulting in deposition of these complexes in various tissues, including the skin. A similar reaction is seen during other infectious diseases, including streptococcal infection, and may happen post-vaccination as viral proteins trigger such immunologic effects. The influenza vaccine had been previously linked to the development of cutaneous immune complex vasculitis, and similar complications have been reported with COVID-19 mRNA vaccines, especially in those with a previous history of vasculitis. Vasculitis has been seen following vaccination with all types of COVID-19 vaccines. Most of the complications developed following the first dose of immunization. The primary manifestations were developed from few hours to 4 weeks after immunization and all the patients showed improvement regardless of receiving various systemic or topical treatment. Cohen et al.

reported leukocytoclastic vasculitis flare following receiving mRNA vaccine in a patient with previous history of psoriasis (9). More importantly, some rare cutaneous inflammation and vasculitis cases have been observed in patients without a remarkable medical history. Larson et al. reported a case of vasculitis following receiving the second dose of

BNT162b2 vaccine in an 83-year-old female. Their patient developed palpable purpuric papules one week after vaccination (10). Like our patient, their patient had an increased C reactive protein level, erythrocyte sedimentation rate, decreased complement, and had cryoglobulinemia (10). Similar to our patient, the skin biopsy showed leukocytoclastic vasculitis. In contrast to our patient, who had a more severe clinical presentation and was infected with SARS-CoV-2 that did not respond to intravenous corticosteroids, their patient was successfully managed with topical corticosteroids (10). Therese Mücke et al. reported a cutaneous immune complex vasculitis case after COVID-19 vaccination in a 76-year-old male who had underlying liver disease (11). They reported that their patient developed pruritic purpuric macules on the lower abdomen, some upper and lower limbs parts, and bloody diarrhea 12 days after receiving the BNT162b2 vaccine. Despite pronounced cutaneous involvement, their patient responded well to steroids (11). In contrast to their patient who had milder clinical symptoms, our patient did not respond to intravenous corticosteroids, and we decided to use plasmapheresis as it has been considered an effective approach in managing immune complex vasculitis (12). Although their patient was the first case report of cutaneous and gastrointestinal immune complex vasculitis following COVID-19 vaccination, the preexisting chronic liver disease could have had a precipitating effect on the development of vasculitis. On the other hand, our patient did not have a previous history of hypersensitivity reactions. Therefore, we may conclude that the vaccine could more probably precipitate the clinical manifestations in our patients. However, the active viral infections, including both hepatitis and SARS-CoV-2 infection following the vaccination, could be a precipitating factor while immune complex vasculitis in different organs has been reported following the severe infection (7).

4. Conclusion

The diagnosis of vaccination-induced vasculitis can be made considering essential factors, including the absence of the previous history of vasculitis or similar cutaneous manifestations. Our patient did not have a previous history of similar cutaneous manifestations of vasculitis, and the development of the symptoms approximately one month from the vaccination suggests immune complex hypersensitivity reaction.

5. Declarations

5.1. Acknowledgement

The authors would like to express their appreciation to patient's family for their kind contributions to this case report.

5.2. Authors' contribution

All authors had substantial contributions to conception and design, acquisition of data, or analysis and interpretation of data, critically revising the manuscript for important intellectual content, and approval of the final version.

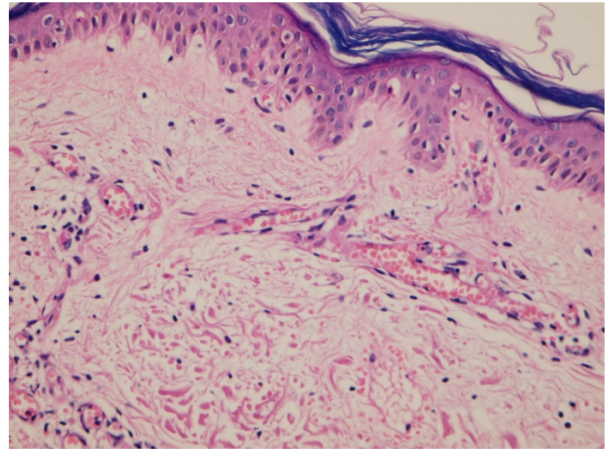


Figure 3 The histopathological evaluation revealed mild vacuolar change of basal layer, subepidermal edema, and mild inflammatory cells infiltration around superficial and deep dermal vessels composed of lymphocytes and neutrophils accompanied by thickening of vascular wall, leukocytoclastic swelling of endothelial cells, red blood cell extravasation, and focal fibrinoid necrosis of vessel wall. No eosinophil was detected. These findings were compatible with small vessel vasculitis

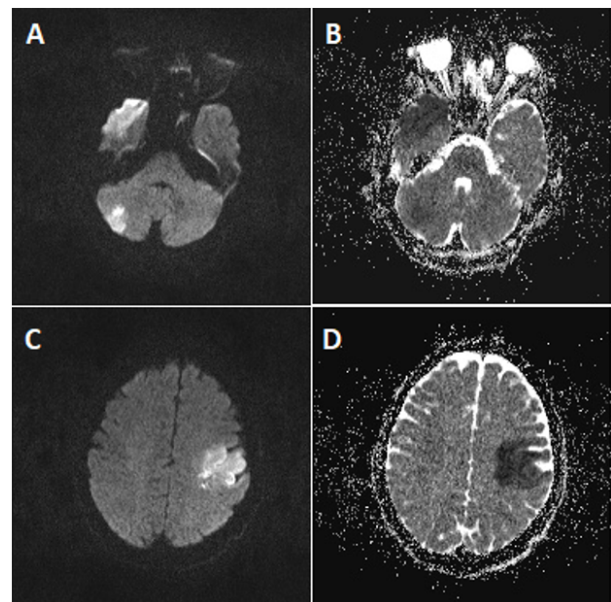


Figure 4 Diffusion weighted magnetic resonance imaging (B value = 1000) shows high signal lesions in right temporal lobe, left parietal lobe, and both cerebellar hemispheres (A and C). The apparent diffusion coefficient (ADC) maps show low signal lesions in these areas suggesting restriction and cytotoxic edema (B and D)

5.3. Conflict of interest

All authors declare that they have no conflict of interest.

5.4. Funding

There is no funding to disclose.

References

1. Wijeratne T, Gillard Crewther S, Sales C, Karimi L. COVID-19 pathophysiology predicts that ischemic stroke occurrence is an expectation, not an exception—a systematic review. *Front Neurol*. 2021;11:607221.
2. Baigi V, Nedjat S, Yunesian M, Akbari Sari A, Mirzaee M, Allameh SE. Clinical and epidemiological features of hospitalized patients with COVID-19 in hospitals of Tehran University of Medical Sciences. *Front Emerg Med*. 2020;5(2):e20.
3. Hanff TC, Mohareb AM, Giri J, Cohen JB, Chirinos JA. Thrombosis in COVID-19. *Am J Hematol*. 2020;95(12):1578-89.
4. Fatima F, Kumar P, Ghosh S, Das A. Post-Covid cutaneous small-vessel vasculitis with features of Koebnerization. *J Cosmet Dermatol*. 2021;00-1-2.
5. Shahidi Dadras M, Zargari O, Abolghasemi R, Bahmanjahromi A, Abdollahimajd F. A probable atypical skin manifestation of COVID-19 infection. *J Dermatolog Treat*. 2020:1-3.
6. Sun Q, Fathy R, McMahon DE, Freeman EE. COVID-19 Vaccines and the Skin: The Landscape of Cutaneous Vaccine Reactions Worldwide. *Dermatol Clin*. 2021;39(4):653-73.
7. McGonagle D, Bridgewood C, Ramanan AV, Meaney JE, Watad A. COVID-19 vasculitis and novel vasculitis mimics. *Lancet Rheumatol*. 2021;3(3):e224-33.
8. Ramadan SM, Kasfiki EV, Kelly CW, Ali I. An interesting case of small vessel pathology following coronavirus infection. *BMJ Case Rep*. 2020;13(9):e237407.
9. Cohen SR, Prussick L, Kahn JS, Gao DX, Radfar A, Rosmarin D. Leukocytoclastic vasculitis flare following the COVID-19 vaccine. *Int J Dermatol*. 2021;60(8):1032-3.
10. Larson V, Seidenberg R, Caplan A, Brinster NK, Meehan SA, Kim RH. Clinical and histopathological spectrum of delayed adverse cutaneous reactions following COVID-19 vaccination. *J Cutan Pathol*. 2022;49(1):34-41.
11. Mücke VT, Knop V, Mücke MM, Ochsendorf F, Zeuzem S. First description of immune complex vasculitis after COVID-19 vaccination with BNT162b2: a case report. *BMC Infect Dis*. 2021;21:958.
12. Goeser MR, Lianosz V, Wetter DA. A practical approach to the diagnosis, evaluation, and management of cutaneous small-vessel vasculitis. *Am J Clin Dermatol*. 2014;15(4):299-306.
13. Bryce C, Grimes Z, Pujadas E, Ahuja S, Beasley MB, Albrecht R, et al. Pathophysiology of SARS-CoV-2: targeting of endothelial cells renders a complex disease with thrombotic microangiopathy and aberrant immune response. *The Mount Sinai COVID-19 autopsy experience*. *MedRxiv*. 2020;Preprint.