

CASE REPORT

DOI: <https://doi.org/10.18502/fem.v6i1.7683>

Acute electrocardiogram pseudoinfarction pattern and reversible left ventricular systolic dysfunction in a patient with diabetic ketoacidosis and hyperkalemia: a case report

Atie Moghtadaie¹, Seyed Amir Miratashi Yazdi², Haleh Ashraf^{3,4}, Abbas Soleimani^{5*}

1. Internal Medicine Department, Sina Hospital, Tehran University of Medical Sciences, Tehran, Iran.

2. General Surgery Department, Sina Hospital, Tehran University of Medical Sciences, Tehran, Iran.

3. Research Development Center, Sina Hospital, Tehran University of Medical Sciences, Tehran, Iran.

4. Cardiac Primary Prevention Research Center (CPPRC), Cardiovascular Diseases Research Institute, Tehran University of Medical Sciences, Tehran, Iran.

5. Department of Cardiology, Sina Hospital, Tehran University of Medical Sciences, Tehran, Iran.

*Corresponding author: Abbas Soleimani; Email: soleimania@yahoo.com

Published online: 2021-09-06

Abstract: Coexisting myocardial infarction (MI) and diabetic ketoacidosis (DKA) are the most common causes of death in diabetic patients. We report a patient with ischemic heart disease manifestations who was finally diagnosed to have DKA as a predisposing factor. The case we present in this paper is a 57-year-old man who was found unconscious in a hotel and presented with complaints of vomiting, abdominal pain, and diarrhea. He had severe dyspnea and chest pain radiating to his back. He had ST-segment elevation in anterior leads on electrocardiogram (ECG), with non-obstructive coronary artery disease in the subsequent heart catheterization. MI patients should be treated with primary percutaneous coronary intervention (PCI) or fibrinolytic agents, but pseudoinfarction due to DKA responds to medical treatment. Thus, it is also important to know that coexistence of both DKA and MI is possible, and neglecting such situations can lead to lethal consequences.

Keywords: Diabetic Ketoacidosis; Myocardial Infarction; Pseudoinfarction; Signs and Symptoms; Systolic Heart Failure

Cite this article as: Moghtadaie A, Miratashi Yazdi S A, Ashraf H, Soleimani A. Acute electrocardiogram pseudoinfarction pattern and reversible left ventricular systolic dysfunction in a patient with diabetic ketoacidosis and hyperkalemia: a case report. *Front Emerg Med.* 2022;6(1):e11.

1. Introduction

Although diabetes mellitus (DM) is associated with many complications, diabetic ketoacidosis (DKA) is one of the most serious ones. Myocardial infarction (MI) is considered a precipitating factor for this condition in one percent of cases (1). DKA, regardless of presence or absence of hyperkalemia, can demonstrate a ST-segment elevation on electrocardiogram (ECG) called pseudoinfarction pattern, which resembles MI (1-4). One of the most challenging issues in case of severe DKA is correct diagnosis and timely treatment of MI (5). Hereby, a patient with DKA and hyperkalemia is reported, who had ST-segment elevation on initial ECG with non-obstructive coronary artery disease in the subsequent heart catheterization. The patient understood that his clinical data would be used for publication purposes and provided consent. Informed consent was obtained from the patient for publication of this case report and any accompany-

ing images.

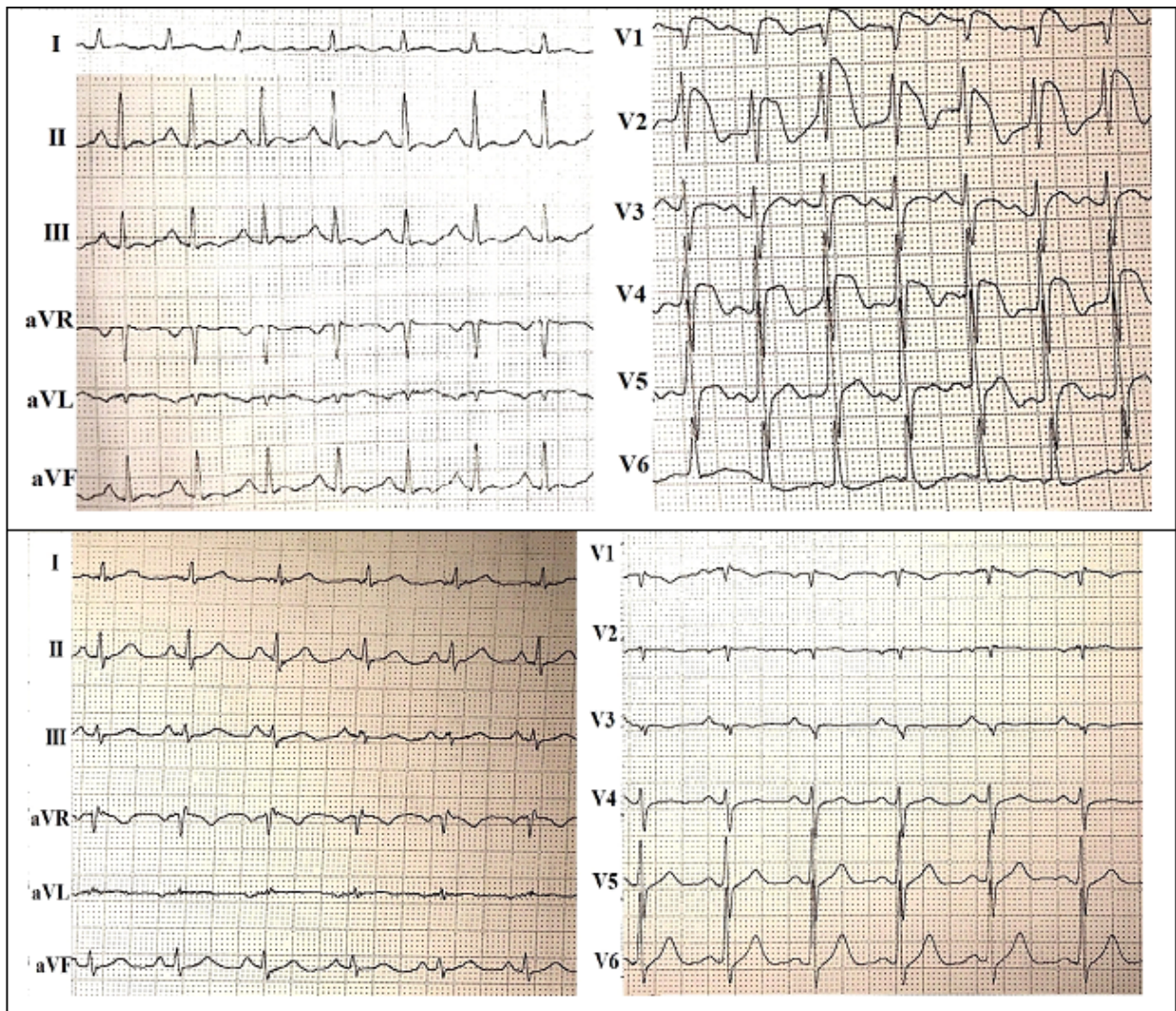
2. Case presentation

A 57-year-old, retired man presented to the emergency department (ED) with complaint of nausea, vomiting, abdominal pain, and diarrhea for five hours before admission. The patient was found with decreased consciousness by the housekeeping staff in a hotel. The patient had been experiencing a pressing type of chest pain in the left hemithorax, radiating to his back, which was accompanied by severe dyspnea. He mentioned heavy smoking in the previous hours and eating a lot of food before experiencing symptoms. There was no history of alcohol or substance use. He was a known case of asthma under treatment with no past medical history of DM; but the patient stated that some time ago his fasting blood sugar had been 110 mg/dl without any follow-up or treatment.

Physical examination on admission revealed a temperature

Table 1 Results of laboratory markers throughout the study

Time (hour)	pH	HCO ₃ (mEq/L)	PCO ₂ (mmHg)	Blood sugar (mg/dL)	Urea (mg/dL)	Creatinine (mg/dL)	Sodium (mEq/L)	Potassium (mEq/L)
Admission	7.05	11.5	40	463	39	1.84	136	5.88
Second	7.06	6.3	21.8	144	N/A	2	140	4.85
Third	7.24	11.7	26.9	135	N/A	N/A	140	4.5
Fourth	7.28	16.4	34.5	N/A	N/A	N/A	N/A	N/A
Fifth	7.32	21.2	40.5	N/A	N/A	N/A	N/A	N/A
Sixth	7.39	24.1	39.1	N/A	N/A	N/A	N/A	N/A
Discharge	7.39	27	28	N/A	N/A	.96	145	3.68

**Figure 1** Electrocardiography on admission (image above) shows ST-segment elevation in precordial leads, which were resolved (image below) during the hospitalization period

of 36.5 degrees centigrade, systolic blood pressure of 80 mmHg, pulse rate of 130 beats per minute, and oxygen saturation of 86 percent. Lung examination revealed generalized wheeze and crackles. He also had peri-umbilical tenderness. The pelvic and abdominal ultrasonography was normal. There was ST-segment elevation in leads V1-V4 in the first ECG (Figure 1). Troponin I level was highly elevated and had reached 1.46 ng/ml (normal range= 0-0.4 ng/ml). The patient underwent emergent coronary catheterization, which revealed minimal coronary artery disease, severe left

ventricular (LV) dysfunction, and cardiogenic shock; 25-49% stenosis in proximal left anterior descending artery and 1-24% stenosis in mid-left anterior descending artery were also detected. LV ejection fraction was estimated to be around 10-15% and LV was enlarged. Severe global hypokinesia was also noted. Meanwhile, the results of venous blood gas (VBG) analysis, blood sugar=463 mg/dL, and presence of ketone in urine confirmed the diagnosis of DKA (Table 1). After leaving the catheterization lab, the DKA treatment protocol was initiated. Due to non obstructive coronary disease, aspirin and

atorvastatin were prescribed. To control diabetes, glargine insulin protocol was initiated for the patient. After initial treatments, echocardiography was performed again, which revealed grade II diastolic dysfunction with pulmonary artery pressure (PAP) of 23 and an ejection fraction (EF) of 40%.

3. Discussion

In this paper, a case of ST-elevation myocardial infarction accompanying DKA with complex symptoms is reported. To have a better understanding of ECG changes in patients with DKA and hyperkalemia we reviewed several case reports of such conditions with suspicion of MI in the literature. A report by Ziakas et al. on a 33-year-old woman showed sinus tachycardia, intraventricular conduction delay and ST-segment elevation in the anteroseptal leads. Cardiac angiography showed normal coronary arteries and these changes were normalized with the treatment of DKA (6). Haseeb et al. reported a 23-year-old diabetic patient who demonstrated right bundle branch block (RBBB), atrial fibrillation, and ST-segment elevation in leads V1-V3, which were compatible with Brugada pattern on baseline ECG. With the initiation of DKA treatment, all changes were resolved (7). The report by Wray et al. on a 19-year-old patient revealed ST-segment elevations in V1 and V2 leads and sinus tachycardia in initial ECG. Further evaluation showed progression of ST-segment elevation to V1, V2, and V3. Catheterization showed normal coronary arteries. Intravenous fluid and insulin therapy led to normalization of ECG changes (8). Sharma et al. also reported ST-segment elevations in V1 and V2 leads of a 43-year-old man's ECG, which returned to normal with DKA therapy (3). Ruiz-morales et al. also noted the same pattern in report of a 47-year-old patient (9).

The majority of case reports on pseudoinfarction in DKA patients have revealed normal LV or reversible LV dysfunction in such patients. Sweterlitsch et al. have reported normal LV function in echocardiography (10). Haseeb et al. reported no wall motion abnormality but noted pericardial effusion with 60% EF (7). Ziakas et al. also reported an intact LV function without segmental wall motion abnormality (6). The report of Abdallah et al. revealed inferolateral wall hypokinesis on echocardiography, which was found to be a sign of silent MI (11). In our study, the patient was in cardiogenic shock state with an EF of 15% on admission. After catheterization and DKA management, EF was increased to 40%. The severity of LV dysfunction can be a clue for differentiation of myocardial infarction and pseudoinfarction pattern in ECG of DKA patients.

Nearly all studies, except for a few, reported negative and undetectable levels of troponin in DKA patients with pseudoinfarction. A study by Sharma et al. reported the level of troponin I to be 0.5 ng/ml, which was not associated with ischemia and coronary artery disease in the angiographic assessment (3). Abdallah et al. presented a 67-year-old patient with DKA who had a baseline troponin I level of 4.88 ng/ml. The angiographic evaluation showed that left circum-

flex artery was totally occluded, which had led to a silent MI (11). Also, in our case, remarkable increase in troponin level was detected.

Aksakal et al. reported a case with acute inferior pseudoinfarction pattern with normal serum potassium level and simultaneous DKA as seen in our study (12). Occasional reports are present about hyperkalemia causing ECG alterations, closely resembling those of acute MI as seen in our study (13). Ruiz-Morales et al. reported a case that illustrated an uncommon reversible ECG finding in a patient with DKA, hyperosmolarity, and hyperkalemia capable of mimicking myocardial infarction (9). But in our study, the potassium and sodium levels were within normal ranges.

Roberts et al. discussed the underlying causes of the prothrombotic state in DKA condition and summarized them as disturbances in activation of platelets, enhanced activity of coagulation cascade, and compromised fibrinolysis (14). However, as demonstrated by Al-Mallah et al., higher levels of troponin I in DKA patients is an indicator of higher risk of mortality and cardiac events in the future (15). The underlying mechanism responsible for myocardial necrosis is not thoroughly elucidated. It is speculated that severe disturbances in acid-base balance and electrolytes might end up triggering spasms of coronary arteries, ultimately causing ischemic myocardial necrosis (11).

The most common condition in which pseudoinfarction pattern develops is DKA-associated hyperkalemia (7). This pattern is not usually observed in hyperkalemia alone (16) and only one case of pseudoinfarction pattern with normal potassium level is available in the current literature (12).

Acute MI and DKA frequently occur simultaneously. It should be always noted that MI can be a precipitating factor for DKA. Neglecting ECG findings of these patients and attributing them to hyperkalemia alone can lead to fatal outcomes. Another concern in these conditions is that DKA itself is accompanied by a slight and non-significant rise in concentrations of serum troponin as in our case, which makes the diagnostic and therapeutic decision-making more problematic and complex (17-19).

Some clues in ECG may facilitate differentiation of myocardial infarction and pseudoinfarction due to hyperkalemia. Tall T-waves are seen in both conditions but they are tall and broad-based with long corrected QT intervals (QTc) in MI, while in hyperkalemia, they are tall and narrow with reduced or normal QTc intervals (20).

4. Conclusion

As previously known, cases with ST-elevation MI need interventions such as fibrinolysis and PCI for their lives to be saved, while cases of pseudoinfarction due to DKA respond well to medical therapy of DKA. Thus, it is important to consider that in DKA patients with ST-segment elevations on ECG, differentiation of these two entities is essential; but it must not be forgotten that coexistence of both MI and DKA is also possible, and neglecting such association can lead to

lethal consequences.

5. Declarations

5.1. Acknowledgment

None.

5.2. Authors' contribution

AS and AM delivered clinical care to the patient and acquired clinical information. AM and SAMY drafted the manuscript. HA revised the manuscript critically and drew the final draft. All authors have critically reviewed and approved the final draft and are responsible for the content of the manuscript.

5.3. Funding

This research did not receive any specific grant from funding agencies in the public, commercial, or not-for-profit sectors.

5.4. Conflict of interest

The authors have no conflicts of interest to declare.

References

- Chakraborty PP, Ray S, Bhattacharjee R, Ghosh S, Mukhopadhyay P, Mukhopadhyay S, et al. First presentation of diabetes as diabetic ketoacidosis in a case of Friedreich's ataxia. *Clin Diabetes*. 2015;33(2):84-6.
- Seth P, Kaur H, Kaur M. Clinical profile of diabetic ketoacidosis: a prospective study in a tertiary care hospital. *J Clin Diagn Res*. 2015;9(6):OC01-4.
- Sharma AM, Wilks J, Aronow HD. Recurrent coronary artery thrombus formation in the setting of diabetic ketoacidosis. *J Invasive Cardiol*. 2011;23(2):E1-4.
- Odubango AA, Kaliseti R, Adrah R, Ajenifuja A, Joseph B, Zaman M. Severe myopericarditis in diabetic ketoacidosis—all troponin are not myocardial infarction. *Clin Med Insights Case Rep*. 2018;11:1179547618763356.
- Gerede DM, Kozluca V, Esenboga K, Aydogan BI, Tutar E. Markedly elevated troponin in diabetic ketoacidosis without acute coronary syndrome. *Turk J Endocrinol Metab*. 2016;20:58-60.
- Ziakas A, Basagiannis C, Stiliadis I. Pseudoinfarction pattern in a patient with hyperkalemia, diabetic ketoacidosis and normal coronary vessels: a case report. *J Med Case Rep*. 2010;4:115.
- Haseeb S, Kariyanna PT, Jayarangaiah A, Thirunavukkarasu G, Hegde S, Marmur JD, et al. Brugada pattern in diabetic ketoacidosis: a case report and scoping study. *Am J Med Case Rep*. 2018;6(9):173-9.
- Wray J, Yoo MJ, Bridwell RE, Tannenbaum L, Henderson J. ST-segment elevation in the setting of diabetic ketoacidosis: is it acute coronary syndrome? *Cureus*. 2020;12(3):e7409.
- Ruiz-Morales J, Canha C, Al-Saffar F, Ibrahim S. Anterior myocardial pseudoinfarction in a patient with diabetic ketoacidosis. *J Geriatr Cardiol*. 2018;15(3):238-40.
- Sweterlitsch EM, Murphy GW. Acute electrocardiographic pseudoinfarction pattern in the setting of diabetic ketoacidosis and severe hyperkalemia. *Am Heart J*. 1996;132(5):1086-9.
- Abdallah M, Raza R, Abdallah T, McCord D, Khoueiry G. A rare case of silent transmural myocardial infarction with diffuse ST elevations complicated by concomitant severe hyperkalemia. *Heart Lung*. 2014;43(4):286-8.
- Aksakal E, Ulus T, Bayram E, Duman H. Acute inferior pseudoinfarction pattern in a patient with normokalemia and diabetic ketoacidosis. *Am J Emerg Med*. 2009;27(2):251.e3-5.
- Lim Y, Anantharaman V. Pseudo myocardial infarct-electrocardiographic pattern in a patient with diabetic ketoacidosis. *Singapore Med J*. 1998;39(11):504-6.
- Roberts JD, Oudit GY, Fitchett DH. Acute coronary thrombosis in a patient with diabetes and severe hyperglycemia. *Can J Cardiol*. 2009;25(6):e217-9.
- Al-Mallah M, Zuberi O, Arida M, Kim HE. Positive troponin in diabetic ketoacidosis without evident acute coronary syndrome predicts adverse cardiac events. *Clin Cardiol*. 2008;31(2):67-71.
- Levine HD, Wanzer SH, Merrill JP. Dialyzable currents of injury in potassium intoxication resembling acute myocardial infarction or pericarditis. *Circulation*. 1956;13(1):29-36.
- Atabek ME, Pirgon O, Oran B, Erkul I, Kurtoglu S. Increased cardiac troponin I concentration in diabetic ketoacidosis. *J Pediatr Endocrinol Metab*. 2004;17(8):1077-82.
- Geddes J, Deans K, Cormack A, Motherwell D, Paterson K, O'Reilly DSJ, et al. Cardiac troponin I concentrations in people presenting with diabetic ketoacidosis. *Ann Clin Biochem*. 2007;44(Pt 4):391-3.
- Abdo AS, Geraci SA. Significance of elevated cardiac troponin I in patients with diabetic ketoacidosis. *J Miss State Med Assoc*. 2013;54(5):127-30.
- Wang K. Images in clinical medicine. "Pseudoinfarction" pattern due to hyperkalemia. *N Engl J Med*. 2004;351(6):593.