

Imaging based learning points

DOI: 10.22114/ajem.v0i0.49

A 56-year-old Diabetic Man with Acute Epigastric PainMehran Sotoodehnia¹, Arash Safaie^{1*}

1. Department of Emergency Medicine, Sina Hospital, Tehran University of Medical Sciences, Tehran, Iran.

*Corresponding author: Arash Safaie; Email: a-safaie@sina.tums.ac.ir

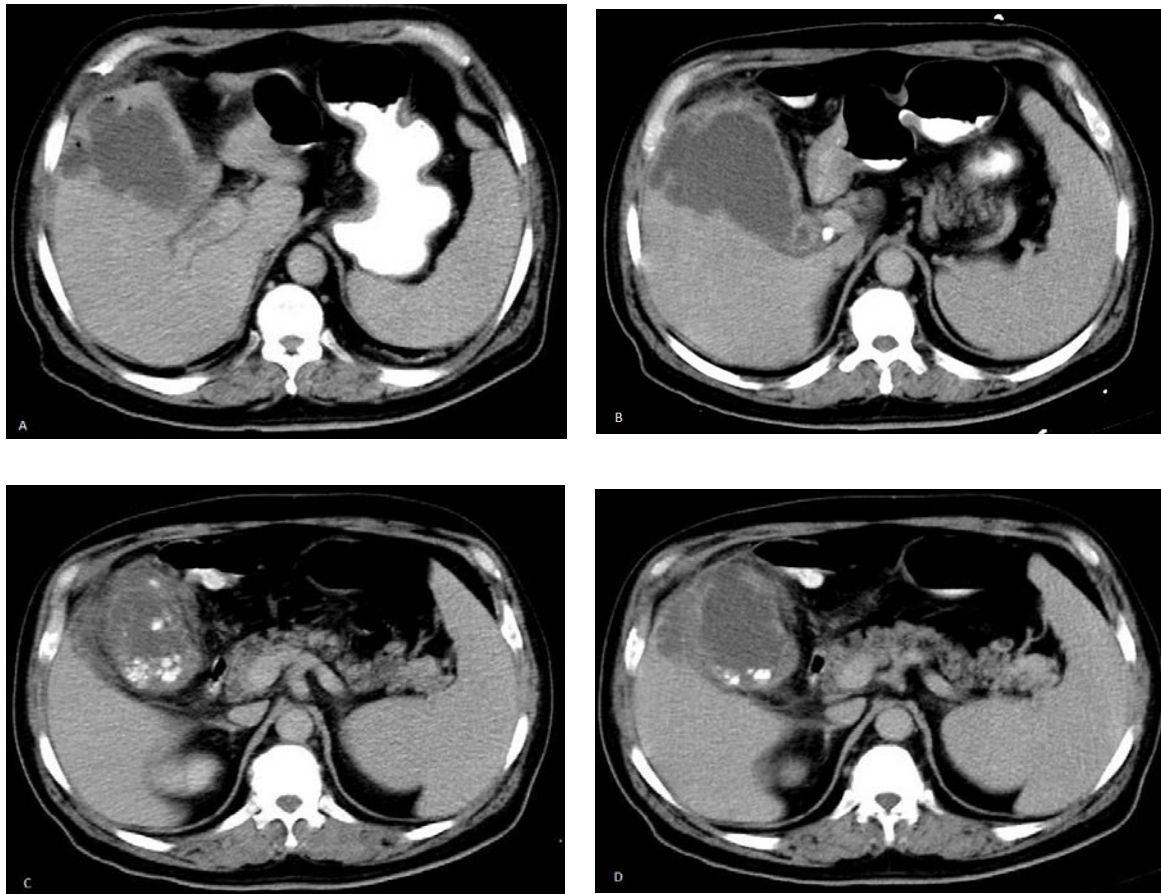


Figure 1: Axial oral and intravenous contrast-enhanced abdominal computed tomography (CT) scan of the patient

KEY QUESTIONS:

- What are the pathologic findings in figure 1?
- What are the differential diagnoses?
- What is the diagnosis?

LEARNING POINTS:**Pathologic findings**

There is air in the wall/lumen of the gallbladder seen as multiple round or linear lucencies (yellow arrows in figure 2A and 2C). Mural enhancement of gallbladder is not seen in this oral and intravenous

contrast-enhanced abdominal computed tomography (CT) scan. The gallbladder wall is irregular, and intraluminal membranes can be seen as irregular intraluminal linear and soft-tissue densities (black arrows in figure 2C). No contrast material can be seen inside the gallbladder. An abnormal loculated and encapsulated fluid attenuation adjacent to the gallbladder consistent with a pericholecystic abscess is another finding in this imaging [shown in figure 2D as (a)]. The gallstones which are seen as hyperdensities within

the gallbladder lumen (shown with blue arrows in figure 2B and 2D), pericholecystic fat stranding which is seen as increased soft-tissue density in the pericholecystic fat (red arrow in figure 2B), and gallbladder distention are the other important imaging findings.

Differential diagnosis

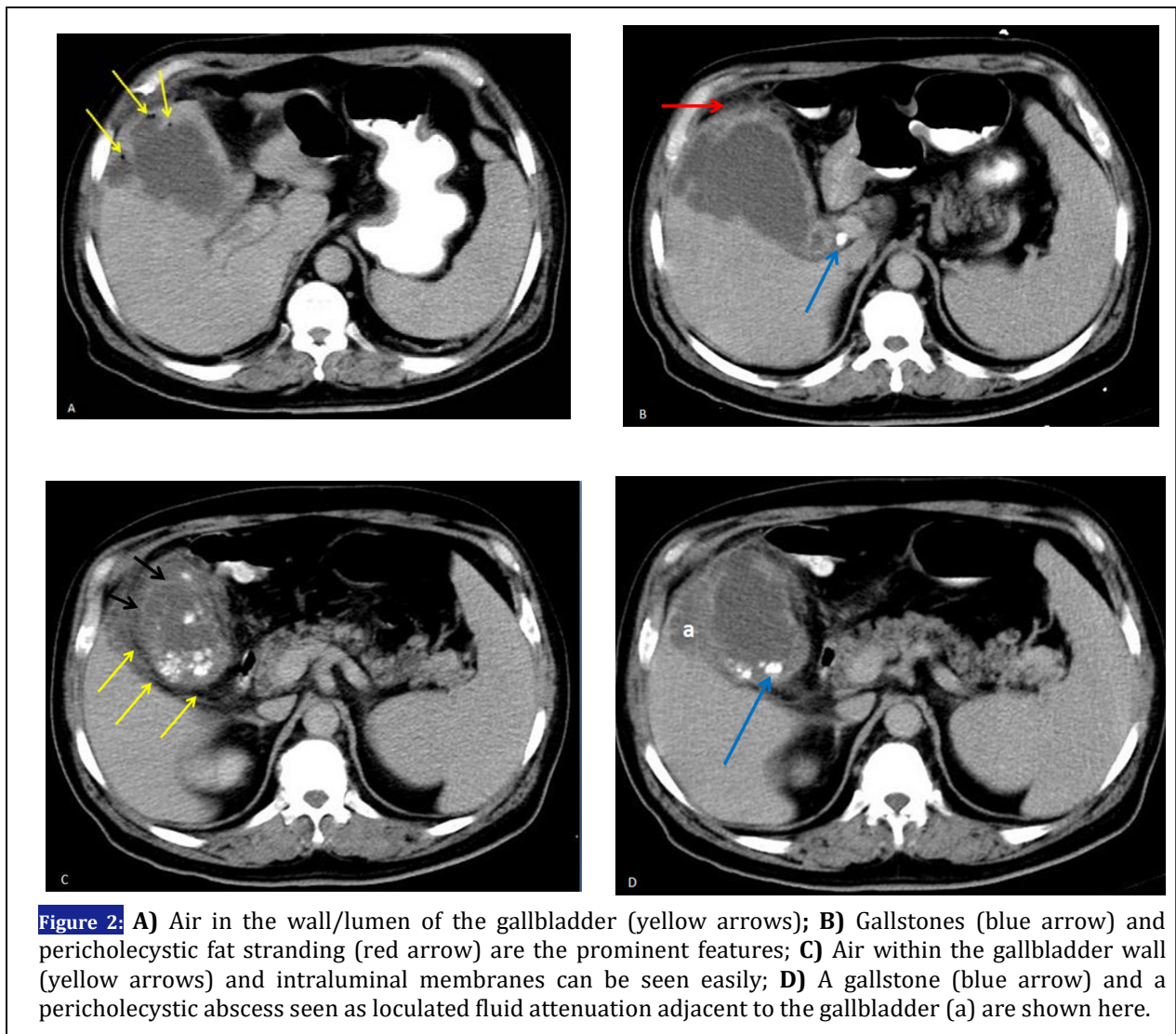
In the absence of any abnormal connection between the biliary system and the gastrointestinal tract, the differential diagnoses are duodenal diverticulitis, hepatic abscess, overlying bowel gas, retro-peritoneal air, focal biliary lipomatosis, and emphysematous pyelonephritis. Other reported causes of gas within the gallbladder in the setting of an abnormal enterobiliary connection include incompetent sphincter of Oddi, enterobiliary surgical anastomosis, spontaneous internal biliary fistula due to gallstone perforation, tumor or traumatic fistula, cholangitis, and effects of drugs

such as magnesium sulfate, dopamine, atropine, and nitroglycerin. In the presence of an enterobiliary fistula, passage of oral contrast agent from the stomach or other parts of the gastrointestinal tract to the biliary system can be seen as intraluminal contrast inside the inflamed gallbladder (1-3).

Diagnosis

Emphysematous cholecystitis also known as gaseous cholecystitis, pneumocholecystitis, or gas gangrene of the gallbladder.

Of all the reported imaging findings, gallbladder distention and wall thickening have been reported as the most sensitive (88%) findings, and gas in gallbladder wall or lumen, intraluminal membranes, irregular or absent wall, and pericholecystic abscess have been considered as the most specific (96.6%–100%) findings for the diagnosis of emphysematous cholecystitis (4, 5).



REFERENCES

1. Rodríguez ÁL, Pavón RF, Rionda PJ, Flores PA, González AF, Gutiérrez CL, et al. "The Effervescent Gallbladder": A Rare Ultrasonographic Finding that Reflects the Presence of Gas within the Gallbladder. *Ultrasound Int Open*. 2015;1(02):E72-E5.
2. Liu Y-P, Yang F-S, Huang J-K. Abnormal radiographic gas patterns in the right upper quadrant. *Am Fam Physician*. 2007;76(12):1853-4.
3. Grayson DE, Abbott RM, Levy AD, Sherman PM. Emphysematous infections of the abdomen and pelvis: a pictorial review. *Radiographics*. 2002;22(3):543-61.
4. Bennett GL, Rusinek H, Lisi V, Israel GM, Krinsky GA, Slywotzky CM, et al. CT findings in acute gangrenous cholecystitis. *AJR Am J Roentgenol*. 2002;178(2):275-81.
5. Sul YH, Song IS. CT Findings of Acute Gangrenous Cholecystitis. *Korean J Hepatobiliary Pancreat Surg*. 2008;12(1):58-63.