

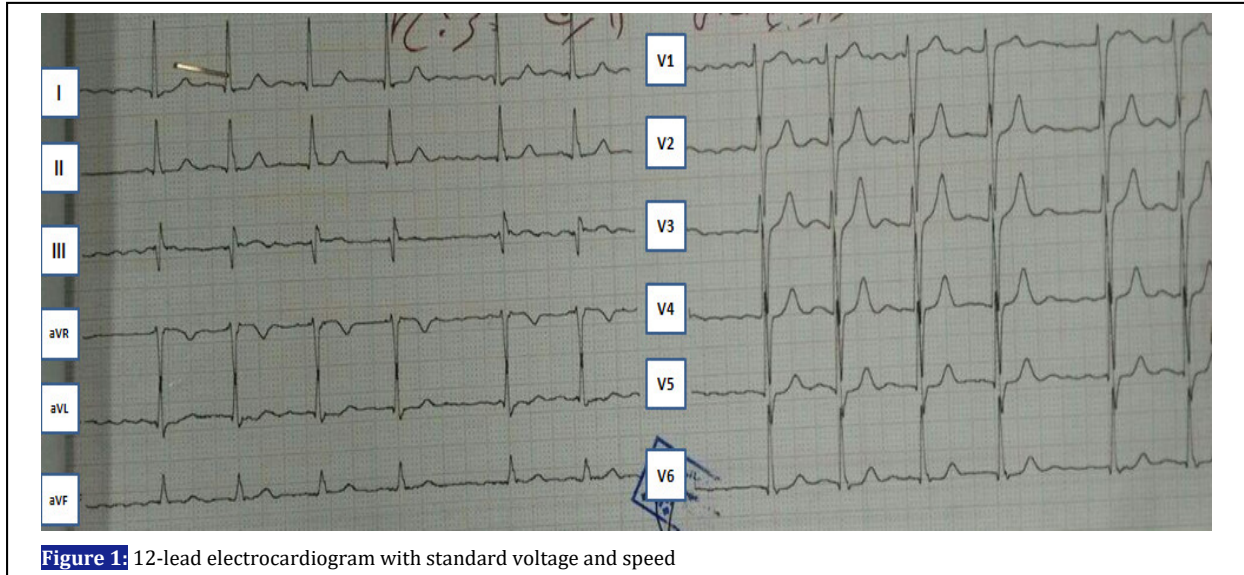
## Electrocardiogram Interpretation

DOI: 10.22114/ajem.v0i0.41

**A 58-Year-Old Woman with Weakness and Shortness of Breath**Mehran Sotoodehnia<sup>1</sup>, Pooya Payandemehr<sup>1\*</sup>

1. Department of Emergency Medicine, Sina Hospital, Tehran University of Medical Sciences, Tehran, Iran.

\*Corresponding author: Pooya Payandemehr; Email: pooya\_mehr@yahoo.com



The patient was a 58-year-old woman with a history of mitral valvuloplasty, presenting to the emergency department (ED) due to weakness and shortness of breath. Her vital signs were stable. The patient's electrocardiogram (ECG) is presented in figure 1. What is the correct interpretation of this ECG?

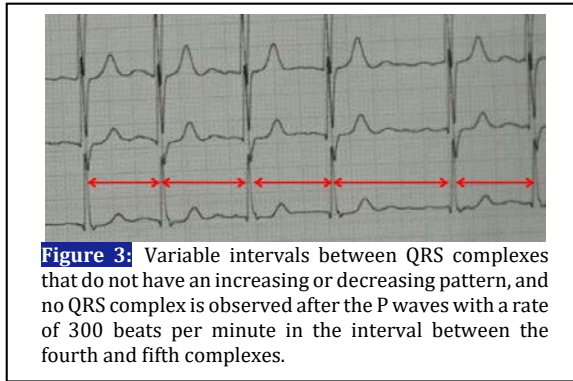
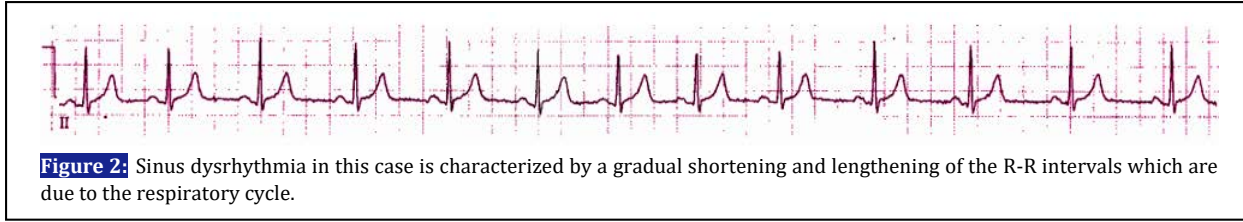
- Sinus dysrhythmia
- Paroxysmal atrial tachycardia with variable AV node block
- Atrial flutter with variable AV node block
- Sinoatrial block
- Atrial fibrillation with normal ventricular rate

The baseline rhythm of this ECG shows an irregularity at the first glance that is repeated without any specific pattern. After considering this irregular abnormal pattern, in the next step, the heartbeat in this ECG should be calculated, taking into account the irregular base rhythm, about six seconds of the ECG should be considered, and the number of complete QRS complexes should be counted in this period. The resulting number should be multiplied by ten in order to estimate the heart rate in a minute. In this patient, the heart rate was about 90 beats per minute. So far, we have an

irregular abnormal rhythm in the ECG. Differential diagnosis of this condition in the ECG varies based on the wide or narrow QRS complexes. A narrow QRS complex is a sign of the natural ventricular depolarization, and several rhythms with a natural rate (60-100 beats per minute) can have irregular QRS intervals. In the case of irregular abnormal rhythms, normal rates, and narrow QRS complexes, there are various differential diagnoses, some of which are mentioned in the multiple choice answer to this question. In the following, after mentioning the electrocardiographic characteristics of each of the rhythms mentioned in the question and their simultaneous assessment in this ECG, we will reach the correct answer.

**Sinus dysrhythmia**

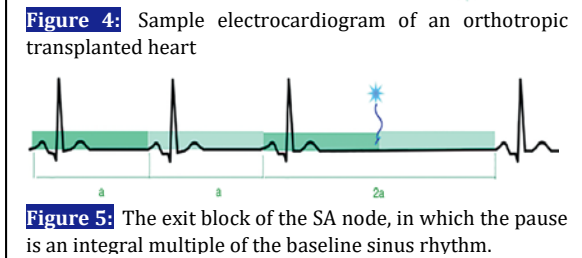
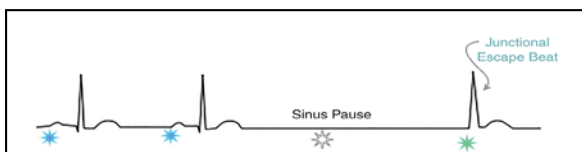
In this rhythm, the P waves have similar shapes, but the P-P intervals vary, which leads to periodic changes in the heart cycle, and the baseline rhythm presents as group beats. In addition, there is a QRS complex after each P wave. In other words, if a longer ECG is taken, changes are seen as irregularities that are regularly repeated. Sinus dysrhythmia may be due to respiratory changes (inhalation decreases the interval between the



complexes and exhalation increases them [figure 2]) or independent of the respiration. The latter is often pathologic (although not significant) and often occurs in the elderly (1, 2). As shown in figure 3, there are no such features in the patient's ECG (the QRS complex intervals marked with two-way arrows vary, and P waves are present in the absence of the QRS complex in some places). This diagnosis is hence rejected and the choice a) is incorrect.

**Sinoatrial block**

This block, also called the sinoatrial node exit block, can be detected in a 12-lead ECG only in its second-degree type. Its diagnostic key is a pause in the regular rhythm of the ECG due to the drop of a P-QRS-T complex. Unlike the sinus pause, in which a P-QRS-T complex is dropped (figure 4), in the second-degree block of SA nodes, the P-P interval during the pause is an (almost integral) multiple of the baseline sinus P-P interval (figure 5) (1, 3).



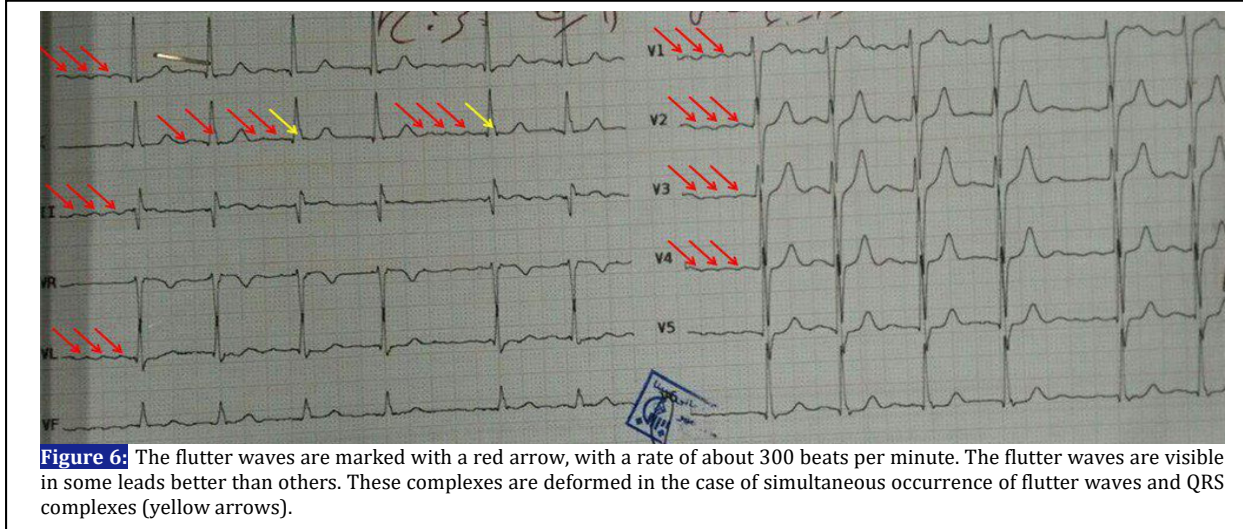
Because P waves are present in the absence of QRS complexes at intervals of pauses, this diagnosis does not apply to the ECG and the choice d) is also incorrect.

**Atrial paroxysmal tachycardia with AV node variable block**

This rhythm is known as "paroxysmal atrial tachycardia (PAT) with block", that is a classic rhythm for digoxin poisoning. The rate of atrial pulse rate is 150-250 beats per minute. The P waveform is different from the P wave generated by the sinus node and is often more prominent in V1. In the presence of a high-level and permanent block of AV nodes (e.g. 2:1, 3:1), QRS complexes are observed at normal speed and at regular intervals. If PAT is associated with a variable block in the AV node (for example, one QRS is directed for two atrial beats, and sometimes it is as 3:1), the rhythm will appear to be irregular (3, 4). In this ECG, the P waves are uniform with a rate of 300 beats per minute, which is clearly higher than paroxysmal atrial tachycardia, but due to the variable block in the AV node, the transfer of the beats to the ventricle occurs variably (as 3:1, 2:1 or 1:1). The patient also had no history of taking digoxin. As a result, this is not a proper diagnosis for this ECG either, so the choice b) is not correct too.

**Atrial flutter with AV node variable block**

It is seen as a regular atrial rhythm, but faster than paroxysmal atrial tachycardia (200-400 beats per minute). A high-level block of the AV node (e.g. 4:1) that occurs in cases of heart disease or medication consumption, results in a regular ventricular response with a normal heartbeat. The "saw-tooth" appearance in the lower leads or V1 is the key to the diagnosis of this rhythm. Sometimes, simultaneous use of cardiovascular medications such as beta-blockers reduces the atrial rate of the flutter waves, which distinguishes it from atrial tachycardia by a saw-tooth appearance in the atrial flutter (3, 4). As you can see in this ECG, the mentioned features are entirely true (figure 6) and the choice c) is correct answer of this question. The P waves associated with the atrial flutter are marked with a red arrow in some places. The yellow arrow refers to the



flutter waves that were created simultaneously with the QRS complex, and have altered the shape of these complexes.

**Atrial fibrillation with a normal ventricular response**

In atrial fibrillation, there is no clear P wave and there are only irregular fluctuations of the baseline. If transmission through the AV node is delayed due to age, disease or medication, atrial fibrillation may result in a normal ventricular response with irregular intervals (5, 6). Regarding the regularity and uniformity of the P waves in this ECG, this diagnosis is also rejected and choice e) is wrong. Other differential diagnoses in the presence of irregular abnormal rhythms with normal rates and narrow QRS complexes include:

- 1- Natural sinus rhythm with premature atrial or junctional contractions
- 2- Sinus pause or arrest
- 3- The second-degree AV node block
- 4- Wandering atrial pacemaker

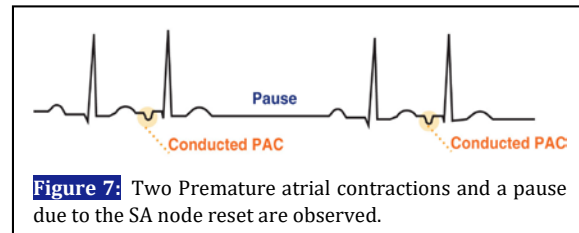
**Normal sinus rhythm with premature atrial or junctional contractions**

There may be one or more premature contractions in a long ECG taken to see the rhythm. These premature contractions can originate from one or more centers in the heart that appear in a regular sinus rhythm as premature impulses (1, 7).

**Premature atrial contractions (PAC)**


It occurs in the P wave with a different shape that appears earlier than expected in the normal sinus rhythm. The form of the P wave, depending on the source of its initiation in the atrium, may be similar to or totally different from the P wave with a sinus

rhythm. The PAC resets the sinus node so that a longer R-R interval is created after the PAC (unless another PAC follows it). This phenomenon does not have much clinical significance and may not be known to the patient. In the PAC, the baseline between the QRS complexes is isoelectric, flat and non-oscillating. The P waves are observed better in lead II and V1 than in other leads (figure 7) (8, 9).



**Premature junctional contractions (PJC)**

It is less prevalent than PAC and does not have much clinical significance. The SA node reset after these beats may or may not occur. PJC is characterized by the appearance of complexes earlier than expected for the appearance of QRS, and there has been no atrial activity prior to these complexes or in case of retrograde conduction of impulse into the atria, the P wave may be seen before, during, or after the QRS complex. The baseline between the QRS complexes, like PACs, is isoelectric, flat and non-oscillating in the PJC, too (figure 8) (10, 11).





**Second-degree atrioventricular block**

The first and third-degree blocks of AV node often have a regular rhythm, but the second-degree block is irregular due to the dropping (non-conduction) of at least one QRS-T complex (12, 13).

explains it results from a change in the pacemaker in the atria or in a change in the conduction. This disorder is rarely of clinical significance (14).

**Wandering atrial pacemaker**

In this disorder, there are three or more of the three P wave forms, each of which has its own QRS complex. The pathophysiology of this disorder

**REFERENCES**

1. Complete Cardiology in a Heartbeat: Healio Learn the Heart; 2017. Available from: <https://www.healio.com/cardiology/learn-the-heart>.
2. Sinoatrial block (SA block): ECG criteria, causes and clinical features 2017. Available from: <https://ecgwaves.com/sinoatrial-block-sa-criteria-ecg-causes-management/>.
3. Surawicz B, Knilans T. Chou's Electrocardiography in Clinical Practice E-Book: Adult and Pediatric: Elsevier Health Sciences; 2008.
4. Hayden GE, Brady WJ, Pollack M, Harrigan RA. Electrocardiographic manifestations: diagnosis of atrioventricular block in the emergency department. *J Emerg Med.* 2004;26(1):95-106.
5. January CT, Wann LS, Alpert JS, Calkins H, Cleveland JC, Cigarroa JE, et al. 2014 AHA/ACC/HRS guideline for the management of patients with atrial fibrillation. *Circulation.* 2014:CIR. 0000000000000041.
6. Chugh SS, Blackshear JL, Shen W-K, Hammill SC, Gersh BJ. Epidemiology and natural history of atrial fibrillation: clinical implications. *J Am Coll Cardiol.* 2001;37(2):371-8.
7. Houghton A, Gray D. Making sense of the ECG: a hands-on guide: CRC Press; 2014.
8. Conen D, Adam M, Roche F, Barthelemy J-C, Dietrich DF, Imboden M, et al. Premature atrial contractions in the general population: frequency and risk factors. *Circulation.* 2012:CIRCULATIONAHA. 112.112300.
9. Wang X, Li Z, Mao J, He B. Electrophysiological features and catheter ablation of symptomatic frequent premature atrial contractions. *Europace.* 2016:euw152.
10. Li J-X, Chen Q, Hu J-X, Yu J-H, Li P, Hong K, et al. Double ventricular response in dual AV nodal pathways mimicking interpolated premature beat. *Herz.* 2017:1-5.
11. Mattu A, Brady WJ. ECGs for the emergency physician 2: John Wiley & Sons; 2011.
12. Ginter JF, Loftis P. Second Degree Atrioventricular Block. *JAAPA.* 2011;24(2).
13. Palmer B, Carroll K. Second-degree atrioventricular block. *Medsurg Nurs.* 2014;23(4):261-3.
14. Wrenn K. Wandering atrial pacemaker and multifocal atrial tachycardia. *ECG in Emergency Medicine and Acute Care: Elsevier;* 2005. p. 101-3.