

Case based learning points

DOI: 10.22114/ajem.v0i0.35

A 58-year-old Man with Abdominal Pain; Acute Appendicitis due to an AppendicolithSeyed Mojtaba Aghili^{1*}, Maryam Kia², Rokhsareh Aghili³

1. Department of Emergency Medicine, Imam Khomeini Hospital Complex, Tehran University of Medical Sciences, Tehran, Iran.

2. Department of Internal Medicine, Ziaiean Hospital, Tehran University of Medical Sciences, Tehran, Iran.

3. Endocrine Research Center, Institute of Endocrinology and Metabolism, Iran University of Medical Sciences, Tehran, Iran.

*Corresponding author: Seyed Mojtaba Aghili; Email: m-aghili@tums.ac.ir

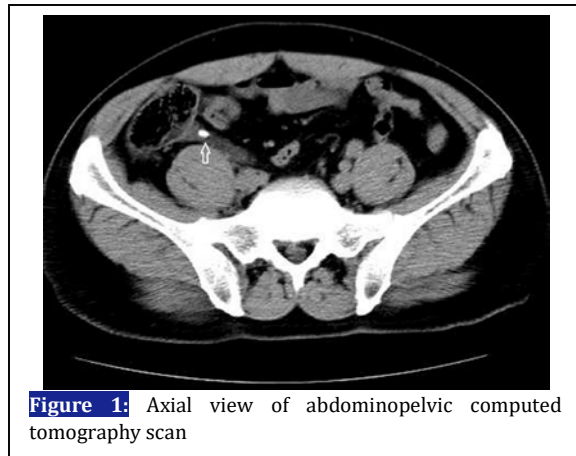
Cite this article as: Aghili SM, Kia M, Aghili R. Jejunal. A 27-years-old Man with Abdominal Pain; Lead Toxicity. Adv J Emerg Med. 2018;2(1): e10.

Figure 1: Axial view of abdominopelvic computed tomography scan

CASE PRESENTATION

A 58-year-old man presented to the emergency department with abdominal pain, nausea and loss of appetite for the last 8 hours. He reported diffuse pain that had been localized to the right lower quadrant (RLQ). Physical examination revealed muscular defense and tenderness in the RLQ.

REFERENCES

1. Hollerman JJ, Bernstein MA, Kottamasu SR, Sirr SA. Acute recurrent appendicitis with appendicolith. Am J Emerg Med. 1988;6(6):614-7.
2. Aljefri A, Al-Nakshabandi N. The stranded stone: relationship between acute appendicitis and appendicolith. Saudi J Gastroenterol. 2009;15(4):258-60.
3. Lowe LH, Penney MW, Schecker LE, Perez R, Jr., Stein SM, Heller RM, et al. Appendicolith revealed on CT in children with suspected appendicitis: how specific is it in the diagnosis of appendicitis? AJR Am J Roentgenol. 2000;175(4):981-4.
4. Niknejad M, Jones J. Appendicolith [30/Mar/2013]. Available from: <http://radiopaedia.org/articles/appendicolith>.

Computed tomography (CT) of the abdomen and pelvis confirmed luminal distension with a thickened enhancing wall with an appendicolith (Figure 1).

LEARNING POINTS

Appendicitis may be developed by an appendicolith, a calcified deposit within the appendix (1). It may be an incidental finding on an abdominal radiograph, ultrasound (US) examination or CT (2). It appears as echogenic focus and casts an acoustic shadow on US examination and manifests as a calcified mass on plain radiograph or CT (3). The incidence of appendicolith is higher among patients with a retrocaecal appendix (4). In our patient, a clinical diagnosis of acute appendicitis was made and the patient was immediately transferred to the operating room and an appendectomy was performed.