

Review Article

DOI: 10.22114/ajem.v0i0.285

Accuracy of Ultrasonography in Diagnosis of Shoulder Dislocation: A Systematic Review

Pouya Entezari^{1,2}, Mohammad Jalili², Javad Seyedhosseini^{1,3}, Amin Doosti-Irani⁴, Hadi Mirfazaelian^{1,2*}

1. Prehospital and Hospital Emergency Research Center, Tehran University of Medical Sciences, Tehran, Iran.
2. Department of Emergency Medicine, Imam Khomeini Hospital Complex, Tehran University of Medical Sciences, Tehran, Iran.
3. Department of Emergency Medicine, Shariati Hospital, Tehran University of Medical Sciences, Tehran, Iran.
4. Department of Epidemiology, School of Public Health, Hamadan University of Medical Sciences, Hamadan, Iran.

*Corresponding author: Hadi Mirfazaelian; Email: h-mirfazaelian@sina.tums.ac.ir

Published online: 2019-10-16

Abstract

Context: This systematic review of clinical trials was conducted to compare the diagnostic accuracy of ultrasound in comparison to plain radiography in shoulder dislocation.

Evidence acquisition: MEDLINE, Cochrane Database of Systematic Reviews, clinicaltrials.gov, Google scholar, and Scopus were searched for clinical trials. Diagnosis of shoulder dislocation and confirmation of shoulder reduction were the outcomes of interest. Sensitivity, specificity, positive predictive value and negative predictive value of included clinical trials were calculated.

Results: Seven studies met our inclusion criteria and were analyzed. All included studies except two had a sensitivity and specificity of 100% for ultrasound (one with a sensitivity of 54% and one with a specificity of 60%).

Conclusion: It can be suggested that ultrasound can be used as a reliable alternative diagnostic method for detection of both dislocation and reduction in shoulder joint. This may decrease the delay in treatment, cost, radiation exposure, and need for repeated sedation.

Key words: Diagnosis; Shoulder Dislocation; Systematic Review; Ultrasonography

Cite this article as: Entezari P, Jalili M, Seyed-Hosseini J, Doosti-Irani A, Mirfazaelian H. Accuracy of Ultrasonography in Diagnosis of Shoulder Dislocation: A Systematic Review. *Adv J Emerg Med.* 2020;4(1):e9.

CONTEXT

Glenohumeral joint has the widest range of motion in the body and dislocate with an incidence rate of 11.2 to 23.9 per 100,000 person-years (1, 2). Conventionally, plain radiography has been used as the standard tool for diagnosing dislocation and confirming reduction. This modality is associated with radiation exposure and a notable risk of diagnosis failure in less common types of dislocation like posterior dislocation (3). Some studies have proposed point-of-care ultrasound as a promising alternative diagnostic method for evaluation of shoulder dislocation (4, 5). It is an available, non-invasive, easily-learned diagnostic tool without any radiation exposure (6). In this systematic review, we intended to evaluate the efficacy of ultrasound in diagnosis of shoulder dislocation and confirmation of should reduction.

EVIDENCE ACQUISITION

Criteria for including studies for this review

All studies comparing ultrasound with plain radiography in shoulder dislocation diagnosis or reduction confirmation were retrieved. These were

included regardless of patients' age, sex, location, publication year, and language. Patients or public were not involved in this study.

Search strategy

We incorporated words "Ultrasound", "Ultrasonography", "Sonography", "Shoulder Dislocation", and "Glenohumeral Dislocation" in order to design a sensitive search strategy. The following databases were included in electronic search: MEDLINE (1950 to February 2017), Cochrane Database of Systematic Reviews (until February 2017), clinicaltrials.gov (January 1992 to February 2017), Google scholar (until February 2017), and Scopus (1960 to February 2017). No language restrictions were applied and the reference lists of included studies were also reviewed.

Data extraction and quality assessment

Two authors (PE, HM) independently screened the title and abstract of potentially relevant articles and excluded duplicates. In the next step, the full text of the identified studies was reviewed to eliminate case studies, and reviews. Data was extracted in terms of the first author, year of

publication, country, age, sample size, gender, type of injury, ultrasound aim, and gold standard diagnostic method. The quality of included studies was assessed using Quality Assessment of Diagnostic Accuracy Studies (QUADAS) scoring system. QUADAS is a validated quality assessment tool for diagnostic accuracy studies, which consists of 14 questions (7). The quality score ranges from 0 to 14, with a high-quality study scoring at least 10. The data was extracted to construct 2 × 2 contingency tables.

Data synthesis

Sensitivity, specificity, positive predictive value, and negative predictive value of ultrasound in the included studies were calculated from 2 × 2 contingency tables. Forest plots of sensitivity and specificity were constructed by Review Manager Version 5.2.

RESULTS

Characteristics of included studies

Figure 1 shows the flow of eligible articles. The search initially produced 7081 records. After removing duplications, potentially eligible records were identified for further review based on review of the title and abstracts. Of those, 7070 studies were excluded due to title and abstract irrelevance or duplication and 11 studies were scrutinized in full text. On full text review, 6 studies were considered eligible and were included in our systematic review (6, 8-13). Of the excluded studies, four were case reports about adult patients and one was a case report about ultrasound diagnosis of posterior shoulder dislocation associated with Erb’s palsy in an infant (3, 4, 14-16). Data was available to construct 2 × 2 contingency tables for all 7 articles that met

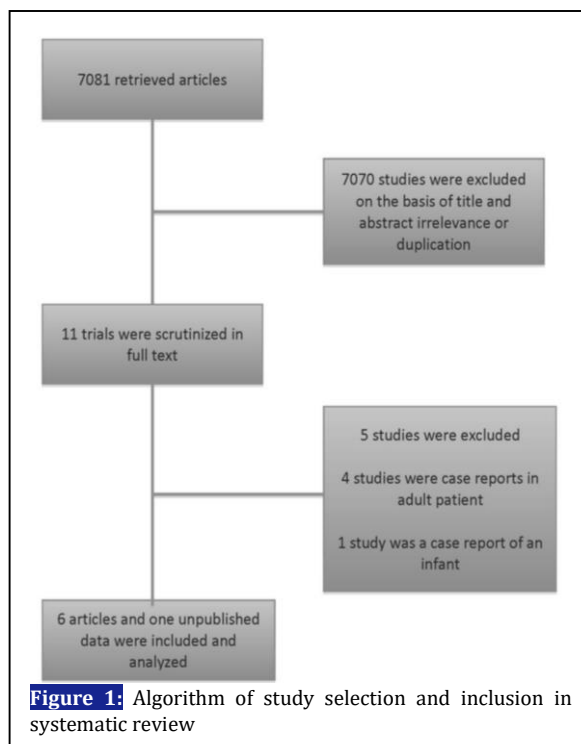


Figure 1: Algorithm of study selection and inclusion in systematic review

inclusion criteria.

Included studies were published from 1994 to 2017 and involved 467 patients in total. There were two studies conducted in the United States, one in the United Kingdom, one in Turkey, and three in Iran. Characteristics of the studies are outlined in table 1. All included studies used plain radiography as the gold standard method for diagnosis of shoulder dislocation or confirmation of shoulder reduction.

Quality assessment and heterogeneity

QUADAS score for quality of the studies is outlined in table 2. We quantified the heterogeneity by I2

Table 1: Characteristics of the included studies

Study	Country	Age	Sample size	Male %	Type of injury	US aim	Gold standard diagnostic method	QUADAS score
Bianchi et al. (1994)	United States	35.5	10	N/A	Dislo. Sub.	Diagnosis before reduction	XR Clin.	12
Blakeley et al. (2008)	United Kingdom	N/A	5	N/A	Dislo.	Diagnosis before & after reduction	XR	13
Abbasi et al. (2013)	Iran	31.63±15.88	73	91.3	Dislo.	Diagnosis before & after reduction	XR	13
Akyol et al. (2015)	Turkey	33.9 ± 15	103	80.6	Dislo.	Diagnosis before & after reduction/Fx exclusion	XR	12
Ahmadi et al. (2016)	Iran	30.11 ±11.41	108	84.3	Anterior Dislo.	Diagnosis after reduction	XR	14
Lahham et al. (2016)	United States	N/A	84	61.9	Anterior Dislo.	Diagnosis before reduction	XR	14
Seyyed Hosseini et al. (2016)	Iran	35.9±15.7	84	83.3	Dislo.	Diagnosis before & after reduction/Fx exclusion	XR	13

N/A: Not available; Dislo: Dislocation; Sub: Subluxation; XR: x-ray imaging; Clin: Clinical findings; Fx: Fracture

Table 2: Diagnostic values of ultrasound imaging in the included studies

Study	TP	FP	FN	TN	Sens. (95%CI)	Spec. (95%CI)	PPV (95%CI)	NPV (95%CI)
Bianchi et al.	2	0	0	5	100% (16%-100%)	100% (48%-100%)	100%	100%
Blakeley et al.	4	0	0	1	100% (40%-100%)	100% (3%-100%)	100%	100%
Abbasi et al.	69	0	0	4	100% (95%-100%)	100% (40%-100%)	100%	100%
Akyol et al.	98	0	0	5	100% (96%-100%)	100% (48%-100%)	100%	100%
Ahmadi et al.	7	0	6	95	54% (25%-81%)	100% (96%-100%)	100%	95% (89.8%-96.6%)
Lahham et al.	19	0	0	64	100% (82%-100%)	100% (94%-100%)	100%	100%
Seyyed Hosseini et al.	78	2	1	3	99% (93%-100%)	60% (15%-95%)	97% (93%-99.1%)	27% (27.4%-96%)

TP: True positive; FP: False positive; FN: False negative; TN: True negative; Sens.: Sensitivity; Spec.: Specificity; PPV: Positive predictive value; NPV: Negative predictive value; 95%CI: 95% confidence interval

Ultrasound

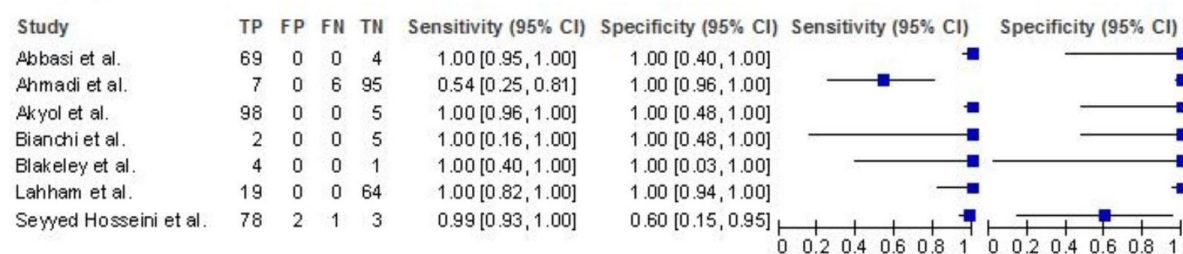


Figure 2: Diagnostic accuracy of ultrasound in comparison to plain radiography

statistics which showed substantial heterogeneity among studies with regard to the variables (17). Therefore, meta-analysis could not be performed.

Diagnostic performance of the ultrasound

Figure 2 shows a Forest plot of sensitivity and specificity of the ultrasound in shoulder dislocation diagnosis. The sensitivity and specificity of included studies ranged from 54-100% and 60-100%, respectively. The diagnostic values of ultrasound imaging in the included studies are outlined in table 2.

DISCUSSION

This systematic review investigated the diagnostic accuracy of ultrasound in comparison to plain radiography in diagnosis of shoulder dislocation. Shoulder joint is the most prevalent major joint in the body to dislocate (1, 11). The longer the joint remains dislocated; the more the complications, recurrences, and reduction failures (18, 19). Therefore, the early identification and management of dislocation is crucial. However, diagnosis is sometimes challenging as physical examination and history may not be sufficient to make the diagnosis (12). Conventionally, plain radiography has been the standard of care for

diagnosis in patients suspected of shoulder dislocation (20). However, as it is associated with several drawbacks so bedside ultrasound has been proposed as a promising alternative diagnostic method for shoulder dislocation. Beside radiation exposure, radiography delays the management and potentially increases the sedation risk in cases of reduction failure, as repeated sedation might be mandatory (21). It was reported that pre-reduction radiograph can delay the management of shoulder dislocation by 29.6±12.68 minutes, and ultrasound uses ultrasound waves instead of radiation and lowers patients' length of stay (8, 12, 21). Furthermore, it improves patient safety by decreasing the sedation risk through reduction confirmation at the bedside while the patient is sedated (4, 5).

There are few studies comparing the accuracy of plain radiography and ultrasound in diagnosis of shoulder dislocation. The majority of included studies compared the diagnostic accuracy in both dislocation identification and reduction verification. Most of the studies were in favor of ultrasound with diagnostic accuracy of about 100%. Of note, Ahmadi et al. found a much lower sensitivity for detection of reduction (53.8%, 95%

CI: 29.1-76.8%) and Seyyed Hosseini et al. found the diagnosis specificity to be 60% (13). The reason for these findings might lie in the operator expertise, training condition, and quality of ultrasound scanner (9). On the other hand, Lahham et al. and Abbasi et al. demonstrated that physicians and non-clinical personnel with minimal training could perform ultrasound accurately enough to detect shoulder dislocation (8, 12).

Results of our study should be interpreted in the context of several limitations. As with any other systematic review, this study was limited by the inevitable heterogeneity of the included studies due to different patient population, operator expertise, and training time, which might play a role (22). In addition, most of the included studies used posterior or anterior examination approaches (10-12), but some used lateral approach (8, 9). In addition, physicians were inevitably non-blinded to the appearance and deformities of shoulder while performing ultrasound, though this is similar to real situation (12). Although financial data is lacking, it appears that ultrasound can be advised as a more cost-effective tool in these patients. Finally, although most patients investigated in the included studies had anterior dislocation, few cases of posterior dislocation were diagnosed successfully. Further studies are required to

determine ultrasound diagnostic performance in this subgroup of patients to substantiate the results.

CONCLUSION

It is suggested that emergency physicians with proper training use ultrasound as a reliable alternative diagnostic method for detection of both dislocation and reduction in shoulder joint. This may reduce the delay in treatment, exposure to radiation, need for repeated sedation, and cost.

ACKNOWLEDGEMENTS

None.

AUTHORS' CONTRIBUTION

MJ conceived the study and provided critical comments on draft. PE and SJS collected the data. PE drafted the manuscript. ADI provided statistical advice on study design and analyzed the data. All authors contributed substantially to its revision. HM takes responsibility for the paper as a whole.

Conflict OF INTEREST

None declared.

FUNDING

None declared.

REFERENCE

1. Kazár B, Relovszky E. Prognosis of primary dislocation of the shoulder. *Acta Orthop Scand.* 1969;40(2):216-24.
2. Zacchilli MA, Owens BD. Epidemiology of shoulder dislocations presenting to emergency departments in the United States. *J Bone Joint Surg Am.* 2010;92(3):542-9.
3. Beck S, Chilstrom M. Point-of-care ultrasound diagnosis and treatment of posterior shoulder dislocation. *Am J Emerg Med.* 2013;31(2):449.e3-5.
4. Halberg MJ, Sweeney TW, Owens WB. Bedside ultrasound for verification of shoulder reduction. *Am J Emerg Med.* 2009;27(1):134.e5-6.
5. Yuen CK, Chung TS, Mok KL, Kan PG, Wong YT. Dynamic ultrasonographic sign for posterior shoulder dislocation. *Emerg Radiol.* 2011;18(1):47-51.
6. Akyol C, Gungor F, Akyol AJ, Kesapli M, Guven R, Cengiz U, et al. Point-of-care ultrasonography for the management of shoulder dislocation in ED. *Am J Emerg Med.* 2016;34(5):866-70.
7. Whiting P, Rutjes AW, Reitsma JB, Bossuyt PM, Kleijnen J. The development of QUADAS: a tool for the quality assessment of studies of diagnostic accuracy included in systematic reviews. *BMC Med Res Methodol.* 2003; 3: 25.
8. Abbasi S, Molaie H, Hafezimoghadam P, Zare MA, Abbasi M, Rezai M, et al. Diagnostic accuracy of ultrasonographic examination in the management of shoulder dislocation in the emergency department. *Ann Emerg Med.* 2013;62(2):170-5.
9. Ahmadi K, Hashemian AM, Sineh-Sepehr K, Afzal-Aghaee M, Jafarpour S, Rahimi-Movaghar V. Bedside ultrasonography for verification of shoulder reduction: A long way to go. *Chin J Traumatol.* 2016;19(1):45-8.

10. Bianchi S, Zwass A, Abdelwahab I. Sonographic evaluation of posterior instability and dislocation of the shoulder: prospective study. *J Ultrasound Med.* 1994;13(5):389-93.
11. Blakeley C, Spencer O, Newman-Saunders T, Hashemi K. A novel use of portable ultrasound in the management of shoulder dislocation. *Emerg Med J.* 2009;26(9):662-3.
12. Lahham S, Becker B, Chiem A, Joseph LM, Anderson CL, Wilson SP, et al. Pilot Study to Determine Accuracy of Posterior Approach Ultrasound for Shoulder Dislocation by Novice Sonographers. *West J Emerg Med.* 2016;17(3):377-82.
13. Seyedhosseini J, Saiidian J, Taheri AH, Vahidi E. Accuracy of point-of-care ultrasound using low frequency curvilinear transducer in the diagnosis of shoulder dislocation and confirmation of appropriate reduction. *Turk J Emerg Med.* 2017;17(4):132-5.
14. Hunter JD, Franklin K, Hughes PM. The ultrasound diagnosis of posterior shoulder dislocation associated with Erb's palsy. *Pediatr Radiol.* 1998;28(7):510-1.
15. Mackenzie DC, Liebmann O. Point-of-care ultrasound facilitates diagnosing a posterior shoulder dislocation. *J Emerg Med.* 2013;44(5):976-8.
16. Yuen C, Mok K, Kan P, Wong Y. Ultrasound diagnosis of anterior shoulder dislocation. *Hong Kong J Emerg Med.* 2009;16(1):29-34.
17. Higgin J, Thompson S, Deeks J, Altman D. Measuring inconsistency in meta-analysis. *BMJ.* 2003;327(7414):557-60.
18. Allen GM. Shoulder ultrasound imaging-integrating anatomy, biomechanics and disease processes. *Eur J Radiol.* 2008;68(1):137-46.
19. Cuffolo G, Coomber R, Burt S, Gray J. Posterior shoulder dislocation while lifting weights: a missed diagnosis. *BMJ Case Rep.* 2014;2014:bcr2013202156.
20. Saul T, Ng L, Lewiss RE. Point-of-care ultrasound in the diagnosis of upper extremity fracture-dislocation. A pictorial essay. *Med Ultrason.* 2013;15(3):230-6.
21. Shuster M, Abu-Laban RB, Boyd J. Prereduction radiographs in clinically evident anterior shoulder dislocation. *Am J Emerg Med.* 1999;17(7):653-8.
22. Brulhart L, Ziswiler H, Tamborrini G, Zufferey P. The importance of sonographer experience and machine quality with regards to the role of musculoskeletal ultrasound in routine care of rheumatoid arthritis patients. *Clin Exp Rheumatol.* 2015;33(1):98-101.