

Case Study

DOI: 10.22114/ajem.v0i0.28

Ultrasound-Guided Emergency Pericardiocentesis of a Patient with Multiple Myeloma in a Resource Limited SettingArpith-Easo Samuel^{1*}, Reshma-Balembi Krishna¹

1. Department of Emergency Medicine, Baby Memorial Hospital, Kerala, India.

*Corresponding author: Arpith Easo Samuel; Email: arpitheasosamuel@gmail.com

Abstract

Introduction: Cardiac tamponade, a variant of cardiogenic shock, is a medical emergency. A traumatic cardiac tamponade is an expected phenomenon; however, in non-traumatic events such as malignant pathology, it is usually less dramatic and takes several days or weeks to manifest. Occurrence of tamponade physiology due to pericardial effusion in a patient with multiple myeloma is a distinctly unusual entity. The involvement of a serous cavity in multiple myeloma is rare and pericardial effusion in such a case is due to restrictive cardiomyopathy or amyloidosis, a presentation late in the course of the disease that carries a grave prognosis.

Case presentation: We present to you a case of a 60-year-old patient with cardiac tamponade due to pericardial effusion secondary to an advanced multiple myeloma. Due to the early diagnosis, she underwent a successful emergency pericardiocentesis with a central venous catheter under ultrasound guidance even in a resource limited emergency department (ED) of a district in southern India. She also showed marked improvement after the procedure and was transferred to the intensive care unit for further management.

Conclusion: Cardiac tamponade is not an "all or none" phenomenon, but rather a continuum of findings. A high index of suspicion and timely clinical decision-making is the key for an emergency physician. Although there are several mimics for cardiac tamponade in ED, it is important for an emergency physician to be aware of such varied presentations of a disease spectrum owing to its rarity and clinical importance.

Key words: Cardiac tamponade; Emergency pericardiocentesis; Multiple myeloma; Resource limited setting

Cite this article as: Samuel AE, Krishna RB. Ultrasound-Guided Emergency Pericardiocentesis of a Patient with Multiple Myeloma in a Resource Limited Setting. *Adv J Emerg Med.* 2018;2(1): e9.

INTRODUCTION

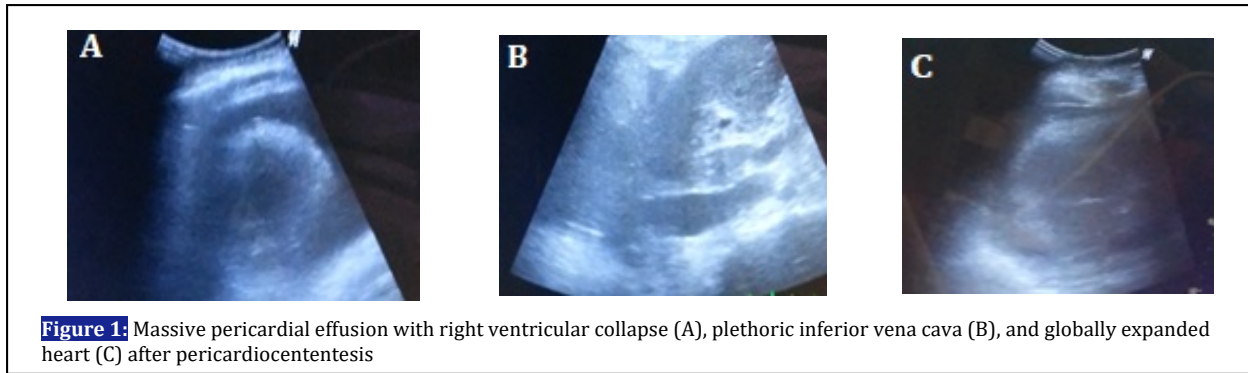
Cardiac tamponade is a life-threatening complication of pericardial effusion and needs immediate intervention. Multiple myeloma presenting with extra osseous manifestations are not uncommon. However, spread of the myeloma to the pericardium, causing effusion, is rarely described and has a poor prognosis with a survival rate of less than 4 months (1). There are a few cases reported with malignant pericardial spread causing pericardial effusion but none with cardiac tamponade (2). The availability of bedside ultrasound in the emergency department (ED) has allowed for more rapid diagnosis of pericardial effusions and cardiac tamponade (3). Here we present the first case of multiple myeloma presenting as cardiac tamponade; the patient underwent emergency pericardiocentesis in the ED of a resource limited setting under ultrasound guidance by an ED physician.

CASE PRESENTATION

A 67-year-old obese female patient with plasma cell leukemia, an aggressive form of multiple

myeloma, was brought into our ED with complaints of generalized tiredness and altered sensorium for 1 day. She had been undergoing treatment for her malignancy at a tertiary care center for 2 years.

On presentation to the ED, her initial physical examination revealed a patent airway, bilateral crackles at the lung base with respiratory rate 30 cycles/min and Spo₂ 70% in room air; her peripheral pulses were feeble, blood pressure unrecordable and heart rate 120 bpm. She was responding to verbal stimulus and had normal finger stick glucose levels. She was pale, had jugular venous distension, and had bilateral pitting pedal edema. Her heart sounds were muffled, without audible murmurs or friction rubs. Neurologic exam findings included no focal deficits and bilaterally equal pupils. Her other physical exam findings were within normal limits. After securing large bore intravenous (IV) lines, she was started on IV fluid resuscitation, cautiously monitoring for the worsening of volume overload. However, she failed to respond



to fluid therapy and hence was started on vasopressor and inotrope supports titrated as per her clinical response. In view of the clinically worsening sensorium and hemodynamic instability she was intubated in the ED. Because her clinical features were consistent with BECK's triad, she was considered to have cardiac tamponade. She was placed on continuous cardiac monitoring and supplemental oxygen through a ventilator. In accordance with the RUSH protocol, a bedside goal-directed ECHO was performed and she was diagnosed as having a massive pericardial effusion. We could observe the right ventricular collapse during diastole (Figure 1 (A)) and plethoric IVC (Figure 1 (B)) and this was an indication for an emergency pericardiocentesis although there was a lack of specific and widely used catheters, namely multi-holed or pigtail. After the necessary counseling and consent, we decided to perform the procedure using a central venous catheter under sonographic guidance in the sub-xiphoid view. We used a PHASED ARRAY probe (2.5–5 MHz), which revealed a 42 mm thickness effusion inferiorly. Using aseptic precautions, an area of 1 cm inferior to the left xiphoid was marked under sterile conditions and a local anesthetic was applied. A trocar needle was introduced and angled at 30° from the skin, aiming toward the left shoulder. Under real-time USG guidance, the pericardial sac was punctured and pericardial fluid aspirated whilst noting the presence of the needle tip in the pericardium. An active aspiration was performed using a 3-way stopcock valve with a syringe. Around 250 ml of fluid was aspirated and the patient was reassessed; she was well perfused, her heart sounds were audible, and her JVD had returned to normal. At this point, her heart had globally expanded within the pericardium, as seen on USG (Figure 1 (C)). The aspiration was stopped; with ongoing support, the patient was transferred to the intensive care team for further management and placement of a pericardial drain *in situ*.

DISCUSSION

This case report highlights the importance of performing a pericardiocentesis at the right time, even in a resource limited setting. Although cardiac tamponade is unusual in multiple myeloma, it can occur. It is needless to say that any clinical uncertainty can easily be overcome by using adjuncts like bedside USG, which can quickly determine the cause of hemodynamic instability in such patients. The sonographic evidence of a cardiac tamponade is the collapse of the right ventricle and atrium during diastole and > 50% dilatation of the inferior vena cava during inspiration (4-7). With sonography, the ideal view depends on the clinician experience, as in our case, we have previously used sub-xiphoid views. However, observational studies recommend the use of parasternal and apical views for superior results (8, 9). This also helps in diagnosis, grading, drainage, and follow up. In terms of equipment a multi-holed, pigtail catheter is ideal; however, a central venous catheter (6–8F) will suffice in a resource limited setting (7).

CONCLUSIONS

A high index of suspicion, understanding the pathophysiology of a disease, anticipating the various clinically unstable situations, appropriate clinical judgment, and timely critical actions could be lifesaving. A well-trained emergency physician can perform these procedures using ultrasound guidance even with limited resources. This case supports the urgent need to provide training in bedside ultrasound during residency to be able to combat such life threatening situations.

ACKNOWLEDGMENTS

We thank the following: Dr Fabith Moideen, Dr Anoop T.C for their valuable guidance; Dr Rajwardhan, intensive care specialist; the residents, nursing, and paramedic staff at Baby Memorial Hospital, Kerala; and Emergency Department at KIMS Kollam, Kerala for providing

infrastructure and other logistic support for this case report.

AUTHORS' CONTRIBUTIONS

A.E.S and R.B.K conceived and designed the report; A.E.S collected and organized the data. R.B.K edited and wrote the manuscript; A.E.S and R.B.K approved the final manuscript.

REFERENCES

1. Retter AS. Pericardial disease in the oncology patient. *Heart Dis.* 2002;4(6):387-91.
2. Garg S, King G, Morginstin M. Malignant pericardial effusion: an unusual presentation of multiple myeloma. *Clin Microbiol Case Rep.* 2015;2(1):010.
3. Mandavia D, Hoffner R, Mahaney K, Henderson S. Bedside echocardiography by emergency physicians. *Ann Emerg Med.* 2001;38(4):377-82.
4. Little WC, Freeman GL. Pericardial disease. *Circulation.* 2006;113(12):1622-32.
5. Maisch B, Seferović PM, Ristić AD, Erbel R, Rienmüller R, Adler Y, et al. Guidelines on the diagnosis and management of pericardial diseases executive summary: the Task Force on the Diagnosis and Management of Pericardial Diseases of the European Society of Cardiology. *Eur Heart J.* 2004;25(7):587-610.
6. Goodman A, Perera P, Mailhot T, Mandavia D. The role of bedside ultrasound in the diagnosis of pericardial effusion and cardiac tamponade. *J Emerg Trauma Shock.* 2012;5(1):72-5.
7. Tsang T, Freeman W, Sinak L, Seward J. Echocardiographically guided pericardiocentesis: evolution and state-of-the-art technique. *Mayo Clin Proc.* 1998;73(7):647-52.
8. Seferović P, Ristić A, Imazio M, Maksimović R, Simeunović D, Trincherro R, et al. Management strategies in pericardial emergencies. *Herz.* 2006;31(9):891-900.
9. Loukas M, Walters A, Boon J, Welch T, Meiring J, Abrahams PH. Pericardiocentesis: a clinical anatomy review. *Clin Anat.* 2012;25(7):872-81.

CONFLICT OF INTEREST

All authors: No reported conflicts of interest. Any conflicts that the editors consider relevant to the content of the manuscript have been disclosed.

FUNDING

No funding from any source was provided or used for this case report.