

## Case based learning points

DOI: 10.22114/ajem.v0i0.221

**Electrical Storm in the Absence of a Structural Heart Disease in a Young Girl**

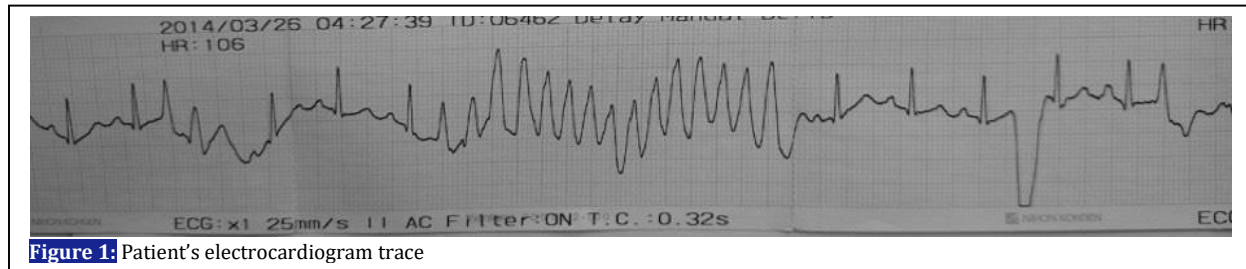
Suhas Rao\*, Anoop T Chakrapani, Ashok Kumar Uppiretla, Donnel Don Bosco

Department of Emergency Medicine, Kerala Institute of Medical Sciences, Trivandrum, India.

\*Corresponding author: Suhas Rao; Email: suhasagastya@gmail.com

Published online: 2019-09-18

**Cite this article as:** Rao S, Chakrapani AT, Uppiretla AK, Don-Bosco D. Electrical Storm in the Absence of a Structural Heart Disease in a Young Girl. *Adv J Emerg Med.* 2020;4(1):e14.



**Figure 1:** Patient's electrocardiogram trace

**CASE PRESENTATION**

A 14-year-old girl presented to the emergency department (ED) with a history of three episodes of seizure-like activity and no comorbidities at 2 am. The first episode had occurred at 6 am, the second at 12 pm and the third two hours before presenting to the ED. Each episode lasting less than 5 minutes, was associated with the limb and spinal rigidity and extension, the up-rolling of eyeballs and urinary incontinence. The patient reported no history of fever, recent trauma, previous febrile seizures, prodromal symptoms, tongue bite, headache or physical excretion before the episodes. No postictal confusion or tonic-clonic movements and significant family history were also reported. The initial examination found her to be conscious, oriented and hemodynamically stable, and the results of her systemic examinations were normal without any significant positive findings.

Evaluation of the patient initiated with the provisional diagnosis of new-onset seizures, followed by performing a computed tomography (CT) scan of the head, which was normal and ruled out any intra-cranial pathology. The results of the blood test involving serum electrolytes, calcium and magnesium were also normal.

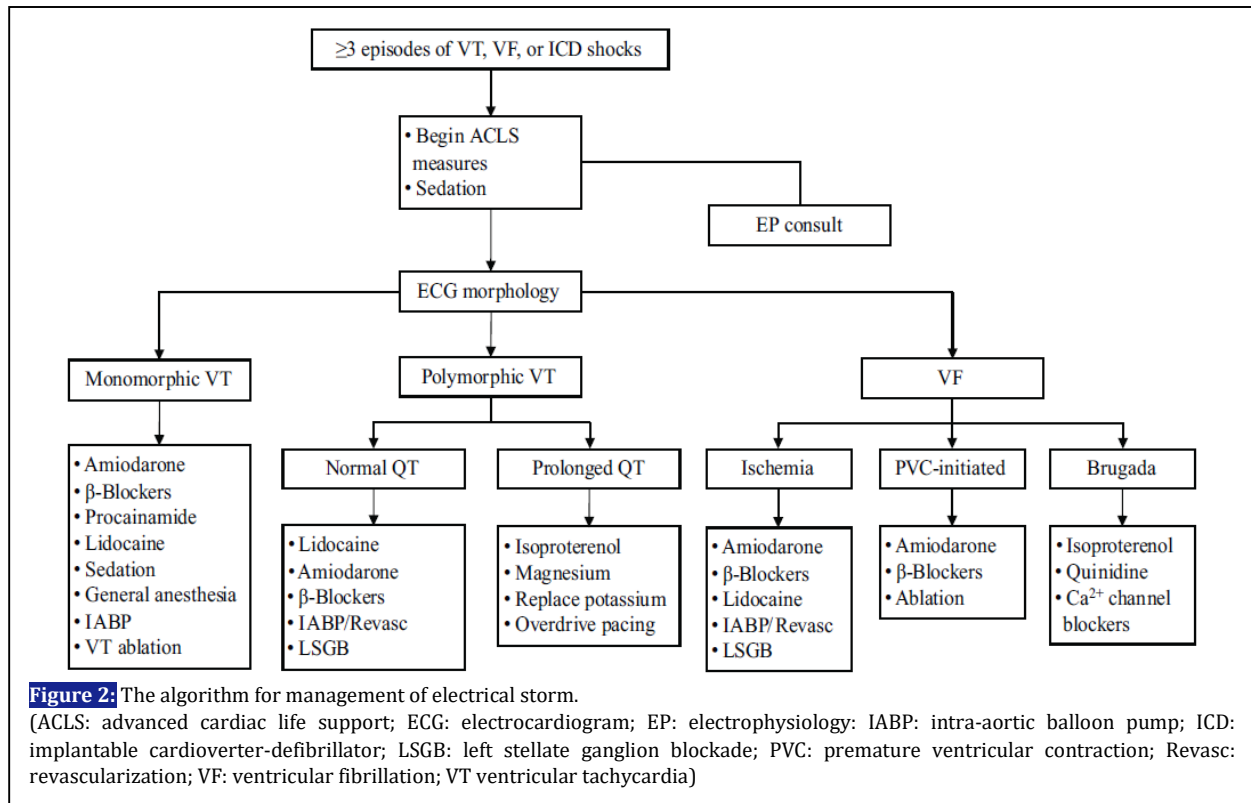
Abrupt polymorphic ventricular tachycardia (VT) was identified on the monitor (figure 1) as a few second-episodes of posturing and stretching of the body with no peripheral and central pulses during the examination in the ED. The patient came around after undergoing cardiopulmonary resuscitation immediately followed by

defibrillation at 200 J and reverting the rhythm to sinus. The patient had recurrent episodes of pulseless polymorphic VT, which required ten times of defibrillation for one hour and antiarrhythmic drug therapy with IV bolus of 300 mg and then again 150 mg amiodarone, and then infusion of 1 mg of magnesium sulfate diluted in 10 ml of D5W and also administration of 1 mg/kg of lidocaine.

The patient was electively intubated and ventilated under deep sedation, and transferred to the cardiac care unit (CCU). The two-dimensional echocardiography findings were revealed normal-sized heart chambers and good left ventricular function. Blood levels of high-sensitivity troponin I and CK-MB were also in their normal range. Despite performing repeated defibrillation and anti-arrhythmic therapy, the patient showed repeated episodes of pulseless VT. She was therefore referred to a higher-level center to be administered with left stellate ganglion block (LSGB). She withstood the procedure, and discharged from the hospital after a ten-day follow-up. An implantable cardioverter-defibrillator (ICD) was later planned for the patient, and she continued with taking oral antiarrhythmic drugs.

**LEARNING POINTS**

Electrical storm refers to the repeated hemodynamic instability associated episodes of VT or ventricular fibrillation (VF) occurring three or more times and treated with anti-tachycardia pacing and defibrillation over 24 hours. Electrical



storm usually occurs with underlying diseases and cardiac disorders, including structural heart diseases such as cardiomyopathy, valve disease and corrected congenital heart disease, ICD implantation during the acute phase of myocardial infarction and inherited arrhythmic syndromes such as Brugada syndrome; However, very rarely occurs with no underlying diseases. An incidence of 10%-28% was reported for electrical storm in observational studies conducted over 1-3 years on ICD implantation performed for the secondary prevention (1-3).

Electrical storm manifests itself with symptoms ranging from simple palpitations and dizziness to more prevalent instances of syncope and more dramatic conditions such as cardiac arrest and multiple episodes of potentially-fatal arrhythmias. Electrical storm can be classified based on the electrocardiogram (ECG) morphology as monomorphic VT, polymorphic VT and VF (3, 4). VT in the absence of structural heart disease is classified into non-life-threatening monomorphic and life-threatening polymorphic rhythms. Typically, polymorphic life-threatening cases include idiopathic VF potentially associated with sudden cardiac arrest in young people and genetic syndromes such as long QT, short QT, Brugada and catecholaminergic polymorphic VT (3-6).

The algorithm for management of electrical storm

shows in figure 2. The treatment of electrical storm begins with defibrillation if the patient is unstable and identifying and correcting the underlying ischemia, electrolyte imbalances and other inciting factors. Treatment alternatives for electrical storm include correction of triggering factors, maintaining the hemodynamic support, pharmacological therapy with antiarrhythmic drugs such as amiodarone, magnesium sulfate and β-blockers, placing ICDs and cardiac sympathetic denervation (3). Transient loss of consciousness accompanied by involuntary movements is not uncommon, and can develop a differential diagnostic dilemma for seizure disorders with important therapeutic and prognostic implications. In addition, failing to properly treat the underlying cardiac condition can significantly increase the risk of mortality. Bearing in mind a clinical suspicion of this failure, obtaining a careful clinical history from available witnesses and the patient, physical examinations and ECG are the most useful diagnostic tools in younger patients (3-7). The present case emphasized on the need for more effective techniques to cope with the transient loss of consciousness and involuntary movements. Early diagnosis and management of life-threatening arrhythmias and electrical storm can help prevent sudden cardiac arrests in younger patients.

**REFERENCE**

1. Moya A, Sutton R, Ammirati F, Blanc JJ, Brignole M, Dahm JB, et al. Guidelines: Guidelines for the diagnosis and management of syncope (version 2009): The Task Force for the Diagnosis and Management of Syncope of the European Society of Cardiology (ESC). *Eur Heart J.* 2009;30(21):2631–71.
2. Brignole M, Hamdan MH. New concepts in the assessment of syncope. *J Am Coll Cardiol.* 2012;59(18):1583-91.
3. Eifling M, Razavi M, Massumi A. The evaluation and management of electrical storm. *Tex Heart Inst J.* 2011;38(2):111–121.
4. Batista A, Liça L, Seixas T, Ribeiro BA, Rodrigues M, Azevedo J, Rodrigues L. Electrical storm in a young woman without prior cardiac history. *Resuscitation.* 2013;84:S14-5.
5. Wever EF, de Medina EO. Sudden death in patients without structural heart disease. *J Am Coll Cardiol.* 2004;43(7):1137-44.
6. Moulik PK, Attar MN, Rose EL, Khaleeli AA. Successful resuscitation of a patient with electrical storm. *Emerg Med J.* 2003 May; 20(3): e4.
7. Gadhinglajkar S, Sreedhar R, Unnikrishnan M, Namboodiri N. Electrical storm: Role of stellate ganglion blockade and anesthetic implications of left cardiac sympathetic denervation. *Indian J Anaesth.* 2013 Jul-Aug; 57(4): 397–400.