

## Case Report

DOI: 10.22114/ajem.v0i0.201

## A Case Report of a Huge Mesenteric Cyst in a 5-Year-Old Girl: A Rare and Challenging Finding in Radiological Assessment

Ahmad Rezaee-Azandaryani<sup>1</sup>, Manouchehr Ghorbanpour<sup>2\*</sup>, Mehrdad Taghipour<sup>2</sup>, Ali Yamini<sup>3</sup>

1. Department of Radiology, Besat Hospital, Hamadan University of Medical Sciences, Hamadan, Iran.

2. Department of General Surgery, Besat Hospital, Hamadan University of Medical Sciences, Hamadan, Iran.

3. Islamic Azad University, Urmia Branch, Urmia, Iran.

\*Corresponding author: Manouchehr Ghorbanpour; Email: manoochehrghorbanpour@gmail.com

Published online: 2019-09-18

### Abstract

**Introduction:** Mesenteric cysts are rare benign intra-abdominal vesicles with various clinical presentations. They almost located in the mesentery of the small intestine. The selective therapeutic method is complete surgical excision, however more than half need resection and bowel anastomosis.

**Case presentation:** Here, we presented a 5-year-old girl with a huge mesenteric cyst (15×14cm<sup>2</sup>) mesenteric cyst that was excised surgically., which the diagnosis confirmed by computed tomography scan and managed through surgical excision.

**Conclusion:** Acute abdominal pain may be due to the presence of mesenteric cysts, but it is not always possible to differentiate and diagnose it preoperatively, and this challenge especially exists in the case of bulky masses. it is recommended to choose primary radical, surgical treatment in case of intra-abdominal cystic mass in the pediatric age.

**Key words:** Case Reports; Mesenteric Cyst; Pediatrics; Radiography

**Cite this article as:** Rezaee-Azandaryani A, Ghorbanpour M, Taghipour M, Yamini A. A Case Report of a Huge Mesenteric Cyst in a 5-Year-Old Girl: A Rare and Challenging Finding in Radiological Assessment. Adv J Emerg Med. 2020;4(2):e31.

### INTRODUCTION

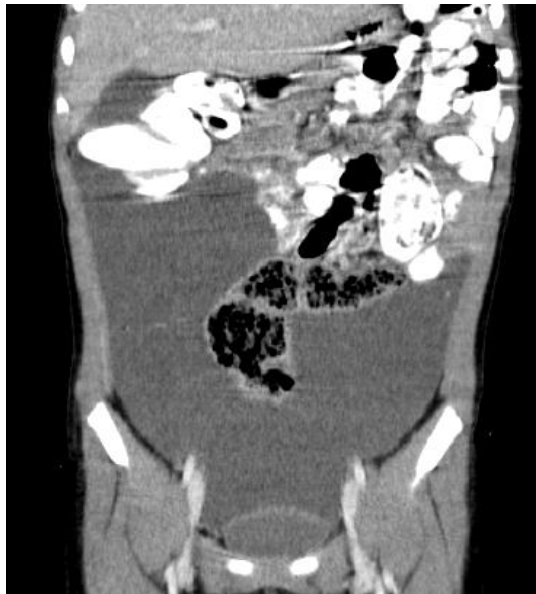Mesenteric cysts are benign and rare abdominal masses that may appear anywhere in the omentum or mesentery of the gastrointestinal tract. There is a possibility of extension from the mesentery to the retroperitoneal regions (1). The incidence of mesenteric and omental cysts has been reported in about 1 case per 20,000 in children, and 1 in 105,000 cases in adult. About one-third of the cases occur in children younger than 15 years old, and the mean age-of-onset is 4.9 years (2). Clinical manifestations of the disease are very diverse and variable, and can occur as a spectrum of asymptomatic abdominal cramps and acute intestinal obstruction (3). Diagnosis is based on clinical and radiological findings. Complete excision of the cystic mass is the best treatment method (4). Since the diagnosis of mesenteric cysts is very challenging due to the lack of pathognomic signs and symptoms, various differential diagnoses and infrequent nature of the disease; therefore, it is worth reporting this case. In this paper, a case of 5-year-old female child who underwent surgical resection for a huge mesenteric cyst was reported.

### CASE PRESENTATION

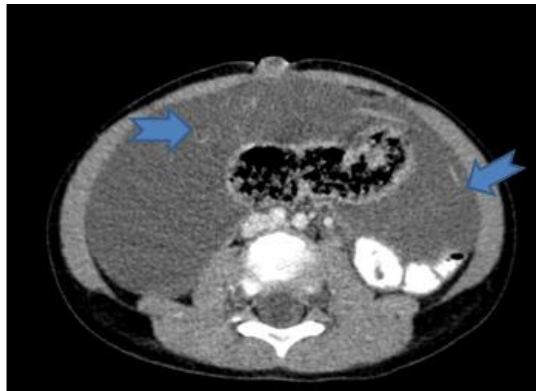
A 5-year-old female child, with a history of

recurrent admissions due to non-specific abdominal pain, referred to the pediatric emergency department of Besat Hospital Hamadan, Iran in December 2018. She had complaints of vague generalized abdominal pain, which began gradually few days before admission. Associated symptoms included nausea, loss of appetite and abdominal swelling in the past recent days. At the physical examination, we found a noticeable abdominal distention, and generalized palpatory tenderness. At the time, the patient was febrile as well.

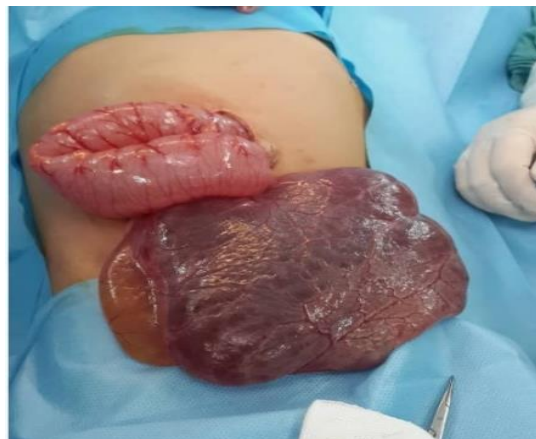Initial laboratory testing showed leukocytosis of  $13.1 \times 10^3/\mu\text{L}$ . The erythrocyte sedimentation rate (ESR) and C-reactive protein (CRP) were tested for any potential inflammation, and reported about 92 mm and positive, respectively. Urinalysis (U/A) was normal and no bacterial growth was found after 24 hours in urine culture. The abdominal ultrasound scan (US) showed a number of cystic lesions with an approximate dimension of 74×100 mm and 43×87 mm in the abdomen and pelvis, respectively. In addition, a picture of a heterozygous lesion, measuring 23×27 mm was seen within one of the cystic lesions, suggesting hematoma. Furthermore, a mild pelvic free fluid was reported.



**Figure 1:** Coronal reconstructed CT image demonstrates large cystic mass lesion surrounded sigmoid colon, and displaced small bowel loops and ascending colon upwardly



**Figure 2:** Axial CT image with IV & oral contrast at the level of umbilicus shows large cystic mass lesion with faint internal septa (arrows) around sigmoid colon, no cyst mural enhancement was seen



**Figure 3:** The huge abdominal cystic mass of the patients that was excised completely

For further examination, a computed tomography (CT) scan was recommended. In the abdominopelvic CT scan performed with an intravenous contrast, a huge cystic mass with approximately 150×140×50 mm in diameter on the right side of the abdomen was observed (Figures 1, 2). Its upper border extended to the lower margin of the liver and the lower extension to the pelvis and adjacent to the bladder. The mass displaced the small intestine and colon to the left side of the abdominal cavity, and it seems to be an intraperitoneal mass. However, due to the mass size, it was impossible to distinguish precisely the retroperitoneal or intraperitoneal masses. The mass contains fine and tiny septa. The suggested differential diagnosis included lymphangiomas, cystic teratomas, and cystic lesions, originated from the adnexa and cystic lesions from the source of peritoneum, as well as infectious cysts (hydatid cyst).

The patient underwent surgery and the huge mass was excised entirely (Figure 3). In order to identify the main identity of the mass, it was sent to the pathology department for further assessments. The patient had a favorable postsurgical evolution, without presenting any complications or recurrences in the past year. The histopathologic examination confirmed the diagnosis of the mesenteric cyst.

#### DISCUSSION

Not much information is available in the literature regarding the treatment of symptomatic cases of mesenteric cysts. In addition to the rare nature of the disease in radiology examinations, it is also very difficult to diagnose such cases, especially in incidences where the patient is referred with non-specific symptoms.

Mesenteric cysts were first described in 1507 by the Italian pathologist Antonio Benivieni (5). Their exact etiology is still unknown. The most accepted theory about the etiology of mesenteric cysts is benign ectopic lymphatic proliferation in the mesentery that are not related to other parts of the mesenteric system (6). It can be found in any regions of the gastrointestinal tract from the duodenum to the rectum in the mesenteric or omentum, and is likely to spread to the retroperitoneal space (7). More than half of the cysts are found in the small bowel mesentery, and particularly are seen in the ileum.

Mesenteric cysts may be isolated as single, multiple and unilocular to multilocular, containing serous, chylous and hemorrhage, or combination of these fluids or infectious fluid (8, 9). The size of

the mesenteric cysts is reported to be less than 40 centimeters. In the reported case, a mass of 15×14 cm existed.

Clinical symptoms of the disease include common gastrointestinal tract disturbances, such as vague abdominal pain, bulging, and palpation of a lump that complicates and presents more severe manifestations, following perforation and torsion or intestinal obstruction (10, 11). In our patient, clinical manifestations were abdominal pain, nausea, and decreased appetite.

Diagnosis of mesenteric cysts is often achieved through prenatal ultrasonography. However, MRI is preferred and recommended in order to confirm the sonographic findings. Ultrasonography provides information such as the size, location, and the presence of intrinsic septal in these cases. Although a CT scan adds little information to sonographic findings, it is advisable to be performed for better identification of the anatomy of the mass, and to determine its association with the surrounding organs (12). The diagnosis of mesenteric cysts is often made by ultrasonography and CT scans, but sometimes the diagnosis is determined only during surgery, due to the complexity of the mass in terms of size and the location. In the CT scan conducted for our patient, an abdominal ascites or hematoma was found. The few differential diagnoses that are commonly arising in such cases include omental cysts, choledochal cysts, hydronephrosis, teratomas, and duplication cysts (13-15).

Mesenteric cysts are classified based on different factors. The most practical ones are the Losanoff pathological classification. It correlates pathological conditions with surgical options and strategies, apart from the nature of cysts. Accordingly, mesenteric cysts are divided into four groups: Type 1: pedicled cysts; type 2: Sessile that are limited to the mesentery and can be excised completely; type 3: Spread to the retroperitoneum, which is often inadequately resected, and type 4: Multicenter cysts requiring complex surgery, sclerotherapy, or both (16).

The standard treatment for mesenteric cysts is

surgical resection. Since the early 1990s, laparoscopic approach has been used as a selective method. However, in cases where the size of the mass is large or there is an excessive adhesion to the surrounding tissues or retroperitoneum, it may be necessary to turn the procedure to an open surgery technique (17). In 20 to 60 percent of cases, resection and enteric anastomosis may be required in addition to the resection of the cysts. In the rare cases, where full intestinal retention is not possible after en-bloc intestinal resection, temporary ileostomy is an appropriate option (18). In a few cases, such cysts have been treated through ultrasound drainage and ethanol sclerotherapy (19).

### CONCLUSIONS

Acute abdominal pain may be due to the presence of mesenteric cysts, but it is not always possible to differentiate and diagnose it preoperatively, and this challenge especially exists in the case of bulky masses. In the present clinical experience, radical excision of the mass was possible, thus allowing having a reliable histological assessment and discovery. Moreover, it avoids any recurrences and complications. In conclusion, it is recommended to choose primary radical, surgical treatment in case of intra-abdominal cystic mass in the pediatric age.

### ACKNOWLEDGEMENTS

None.

### AUTHORS' CONTRIBUTION

All the authors fulfil the criteria of authorship based on the recommendations of the International Committee of Medical Journal Editors (ICMJE).

### CONFLICT OF INTEREST

None declared

### FUNDING

None declared

### REFERENCES

1. Fernandez Ibieta M, Rojas Ticona J, Martinez Castano I, Reyes Rios P, Villamil V, Giron Vallejo O, et al. Mesenteric cysts in children. *An Pediatr (Barc)*. 2015;82(1):e48-51.
2. Giannos A, Stavrou S, Goumalatsos N, Fragkoulidis G, Chra E, Argiropoulos D, et al. Mesenteric cysts and mesenteric venous thrombosis leading to intestinal necrosis in pregnancy managed with laparotomy: a case report and review of the literature. *J Med Case Rep*. 2017;11(1):184.
3. Paramythiotis D, Bangeas P, Karakatsanis A, Iliadis A, Karayannopoulou G, Michalopoulos A. Ideal treatment strategy for chylous mesenteric cyst: a case report. *J Med Case Rep*. 2018;12(1):317.

4. Marte A, Papparella A, Prezioso M, Cavaiuolo S, Pintozzi L. Mesenteric cyst in 11-year old girl: A technical note. Case report. *J Pediatr Surg Case Rep.* 2013;1(4):84-6.
5. Mohamed F. Pediatric abdominal chylolymphatic cysts: Sneaky abdominal masqueraders. *Turk J Surg.* 2018;1-3.
6. Belhassen S, Meriem B, Rachida L, Nahla K, Saida H, Imed K, et al. Mesenteric cyst in infancy: presentation and management. *Pan Afr Med J.* 2017;26:191.
7. Ferrero L, Guana R, Carbonaro G, Cortese MG, Lonati L, Teruzzi E, et al. Cystic intra-abdominal masses in children. *Pediatr Rep.* 2017;9(3):7284.
8. Luo CC, Huang CS, Chao HC, Chu SM, Hsueh C. Intra-abdominal cystic lymphangiomas in infancy and childhood. *Chang Gung Med J.* 2004;27(7):509-14.
9. Hebra A, Brown MF, McGeehin KM, Ross AJ, 3rd. Mesenteric, omental, and retroperitoneal cysts in children: a clinical study of 22 cases. *South Med J.* 1993;86(2):173-6.
10. Paradies G, Zullino F, Orofino A, Leggio S. Rare extragonadal teratomas in children: complete tumor excision as a reliable and essential procedure for significant survival. Clinical experience and review of the literature. *Ann Ital Chir.* 2014;85(1):56-68.
11. Yoon JW, Choi DY, Oh YK, Lee SH, Gang DB, Yu ST. A Case of Mesenteric Cyst in a 4-Year-Old Child with Acute Abdominal Pain. *Pediatr Gastroenterol Hepatol Nutr.* 2017;20(4):268-72.
12. Mullaney TG, D'Souza B. Mesenteric cyst: an uncommon cause of acute abdomen. *ANZ J Surg.* 2019;89(3):E98-e9.
13. Geramizadeh B. Isolated Peritoneal, Mesenteric, and Omental Hydatid Cyst: A Clinicopathologic Narrative Review. *Iran J Med Sci.* 2017;42(6):517-23.
14. Delvincourt M, Godfrey EM, Duckworth A, Carroll NR. A case of lymphangioma-like mesenteric cysts diagnosed as adenocarcinoma of possible pancreatic origin on EUS-FNA. *Gastrointest Endosc.* 2018;87(5):1359-61.
15. de la Plaza Llamas R, Ramia Angel JM, Garcia Amador C, Lopez Marcano AJ. Chylous Mesenteric Cyst. *J Gastrointest Surg.* 2018;22(5):921-2.
16. Yamabuki T, Suzuoki M, Murakami T, Hirano S. Laparoscopic Resection of a Jejunal Mesenteric Pseudocyst. *Case Rep Gastroenterol.* 2017;11(3):526-30.
17. Leung BC, Sankey R, Fronza M, Maatouk M. Conservative approach to the acute management of a large mesenteric cyst. *World J Clin Cases.* 2017;5(9):360-3.
18. Razi K, Al-Asaad O, Milind R. Case report: elective removal of a large mesenteric cyst-our approach. *J Surg Case Rep.* 2017;2017(3):rjx063.
19. Souftas VD, Kosmidou M, Karanikas M, Souftas D, Menexes G, Prassopoulos P. Symptomatic abdominal simple cysts: is percutaneous sclerotherapy with hypertonic saline and bleomycin a treatment option? *Gastroenterol Res Pract.* 2015;2015:489363.