

## Case Study

DOI: 10.22114/ajem.v0i0.185

# Management of a Penetrating Thoracic Injury with Thoracoscopy; A Case Study

Hossein Zabihi<sup>1,2</sup>, Pezhman Farshidmehr<sup>1</sup>, Reza Hajebi<sup>1</sup>, Ehsan Rahimpour<sup>1</sup>, Payam Vezvaei<sup>1,2\*</sup>

1. Department of Surgery, Tehran University of Medical Sciences, Tehran, Iran.

2. Sina Trauma and Surgery Research Center, Tehran University of Medical Sciences, Tehran, Iran.

\*Corresponding author: Payam Vezvaei, Email: payam.vezvaei@gmail.com

Published online: 2019-07-01

**Abstract**

**Introduction:** Various strategies could be considered dealing with penetrating thoracic injuries. Thoracoscopy is much less invasive than routine thoracotomy approach for managing such cases in which the sharp object remains in the body. The case presented in this article was managed with thoracoscopy for a penetrating dorsolateral thoracic injury.

**Case Presentation:** A 35-year-old man with a penetrating dorsolateral thoracic injury referred to the emergency department. Despite an elevated pulse rate, the patient has proper blood pressure and O<sub>2</sub> saturation. Considering the patient's stability and the results of imaging which did not show any massive vascular injury, the patient was taken to the operation room for thoracoscopy. At thoracoscopy, we saw 4 cm of the blade in the thoracic cavity between the third and fourth intercostal space. There was a mild laceration of lung tissue without any active bleeding. Considering the position of the blade and the absence of active bleeding and vascular injury at the trauma site, we successfully removed the blade by the thoracoscope without any complications.

**Conclusion:** Our experience of removing a retained knife by thoracoscopy showed that it can be an appropriate alternative for patients with penetrating thoracic injury who are hemodynamically stable and have appropriate conditions for thoracoscopy.

**Key words:** Case Management; Implements in-situ; Thoracic Injuries; Thoracoscopy; Wounds, Penetrating

**Cite this article as:** Zabihi H, Farshidmehr P, Hajebi R, Rahimpour E, Vezvaei P. Management of a Penetrating Thoracic Injury with Thoracoscopy; A Case Study. Adv J Emerg Med. 2020;4(1):e11.

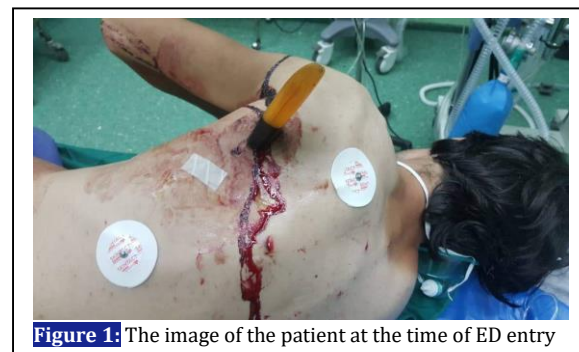**INTRODUCTION**

Dorsal penetrating thoracic injuries are commonly caused by sharp objects or bullets (1). The mortality rate of thoracic traumas is reported to be between 3.6% and 37% (2). They may be asymptomatic or in some cases, severely life threatening. They are usually complicated and require surgical treatment to save the patients (3). Various strategies could be considered dealing with such cases. Thoracoscopy is much less invasive than routine thoracotomy approach for managing patients with penetrating thoracic injuries in which the sharp object remains in the body. The case presented in this article was managed with thoracoscopy for a penetrating dorsolateral thoracic injury.

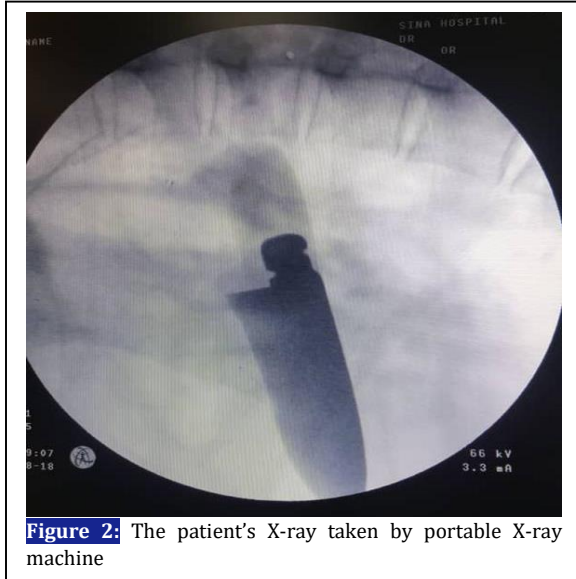**CASE PRESENTATION**

The patient was a 35-year-old man with a penetrating dorsolateral thoracic injury. The patient was injured by a knife through a street quarrel and brought to the emergency department (ED) by ambulance. The knife had entered the

thoracic cavity from lateral to the left mid-clavicle line posteriorly at the level of the third intercostal space with about 4 cm of the blade inside the body (Figure 1). Hematoma was detected at the site of the injury. Despite an elevated pulse rate (110 bpm), the patient was stable with the arterial blood pressure of 110/70 mmHg, respiratory rate of 18 and oxygen saturation of 96% in room air. We evaluated the patient by extended focused assessment with sonography in trauma (e-FAST)



**Figure 1:** The image of the patient at the time of ED entry

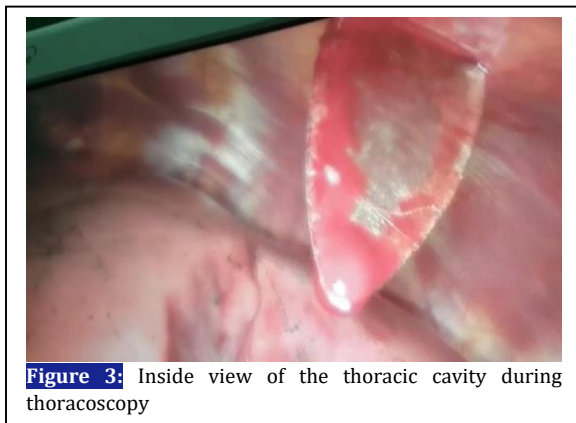


**Figure 2:** The patient's X-ray taken by portable X-ray machine

protocol which revealed possible pneumothorax, but no sign of hemothorax was observed. There was no abdominal free fluid and we did not detect any sign of pericardial effusion. The knife at the injury site did not allow performing anterior-posterior Chest X-Ray (CXR), therefore, a hemi-lateral CXR was taken to evaluate the extension of the injury. The radiograph was taken using a portable X-ray machine (Figure 2).

Considering the patient's stability and the results of imaging which did not show any massive vascular injury, the patient was taken to the operation room for thoracoscopy. We intended to have a better vision of the injury and remove the knife with thoracoscopy, and avoid wide thoracotomy, which is the routine treatment for patients with penetrating thoracic injuries.

At thoracoscopy, we saw 4 cm of the blade in the thoracic cavity between the third and fourth intercostal space (Figure 3). There was a mild laceration of lung tissue without any active



**Figure 3:** Inside view of the thoracic cavity during thoracoscopy

bleeding. Considering the position of the blade and the absence of active bleeding and vascular injury at the trauma site, we successfully removed the blade by the thoracoscope without any complications. After removing the knife, we observed the site of the injury directly via the thoracoscope for 15 minutes to detect any sign of bleeding or complication. Because the patient was stable and no complications were detected, we removed the thoracoscope. We placed a chest tube at the same place the thoracoscope entered the thoracic cavity to avoid an extra scar. About 300 cc of blood was drained through the chest tube. We closed the site of the injury with 0-USP Braided – non absorbable SILK. We also performed an echocardiography to make sure that there was no sign of pericardial effusion.

The patient was taken to the ICU. After one day, the chest tube did not drain any further fluid, the patient was stable and examinations were completely normal. Therefore, we decided to transfer the patient to the general ward where he was discharged after 5 days without any complications.

#### DISCUSSIONS

The unusual appearance of penetrating thoracic injuries, specially retained knife, may distract the medical team and focus their attention on the retained knife rather than the initial resuscitation and patient's stability (4). A complete systematic examination is necessary, followed by assessing the depth of the injury and searching for possible vascular and neuromuscular injuries. Patients with vascular injuries may have normal arterial blood pressure and pulse rate since the blade can prevent hemorrhage by acting as a tamponade (4, 5).

The retained knife should be extracted cautiously because it may cause severe hemorrhage, hemodynamic deterioration and death (5). Thoracotomy is usually necessary in patients with penetrating thoracic injury especially in patients with the sharp object retained at the injury site. Thoracotomy allows surgeons to evaluate great vessel injuries and the extension of the penetration, and to remove the sharp object without any further damage (4). However, thoracotomy is an extremely invasive procedure which may result in infection, thromboembolism, lung injury, chronic post-thoracotomy pain, intercostal nerve injury, etc. (6-8). Alternative approaches wherever possible will reduce these complications and result in better patient care and decreased costs.

**CONCLUSIONS**

Our experience of removing a retained knife by thoracoscopy showed that it can be an appropriate alternative for patients with penetrating thoracic injury who are hemodynamically stable and have appropriate conditions for thoracoscopy.

**ACKNOWLEDGMENTS**

None.

**REFERENCES**

1. Battistella F, Benfield JR. Blunt and penetrating injuries of the chest wall, pleura and lungs. General thoracic surgery 5th ed Philadelphia: Lippincott Williams & Wilkins. 2000:815-31.
2. Ali J, Gana TJ, Howard M. Trauma mannequin assessment of management skills of surgical residents after advanced trauma life support training. *J Surg Res.* 2000;93(1):197-200.
3. Demetriades D, Kimbrell B, Salim A, Velmahos G, Rhee P, Preston C, et al. Trauma deaths in a mature urban trauma system: is "trimodal" distribution a valid concept? *J Am Coll Surg.* 2005;201(3):343-8.
4. Thomson BN, Knight SR. Bilateral thoracoabdominal impalement: avoiding pitfalls in the management of impalement injuries. *J Trauma.* 2000;49(6):1135-7.
5. Sobnach S, Nicol A, Nathire H, Kahn D, Navsaria P. Management of the retained knife blade. *World J Surg.* 2010;34(7):1648-52.
6. Ziomek S, Read RC, Tobler HG, Harrell JE, Gocio JC, Fink LM, et al. Thromboembolism in patients undergoing thoracotomy. *Ann Thorac Surg.* 1993;56(2):223-7.
7. Rogers ML, Duffy JP. Surgical aspects of chronic post-thoracotomy pain. *Eur J Cardiothorac Surg.* 2000;18(6):711-6.
8. Rogers M, Henderson L, Mahajan R, Duffy J. Preliminary findings in the neurophysiological assessment of intercostal nerve injury during thoracotomy. *Eur J Cardiothorac Surg.* 2002;21(2):298-301.

**AUTHORS' CONTRIBUTION**

The author passed four criteria for authorship contribution based on recommendations of the International Committee of Medical Journal Editors.

**CONFLICTS OF INTEREST**

None declared.

**FUNDING**

None declared.