

Imaging based learning points

DOI: 10.22114/ajem.v0i0.144

An 85-year-old Woman with Altered Mental Status and HypotensionMehran Sotoodehnia¹, Atefeh Abdollahi^{1*}, Maryam Khodayar²

1. Department of Emergency Medicine, Sina Hospital, Tehran University of Medical Sciences, Tehran, Iran.

2. Imam Hossein Center for Education, Research and Treatment, Shahrood University of Medical Sciences, Shahrood, Iran.

*Corresponding author: Atefeh Abdollahi; Email: aabdollahi@sina.tums.ac.ir

Published online: 2019-04-27

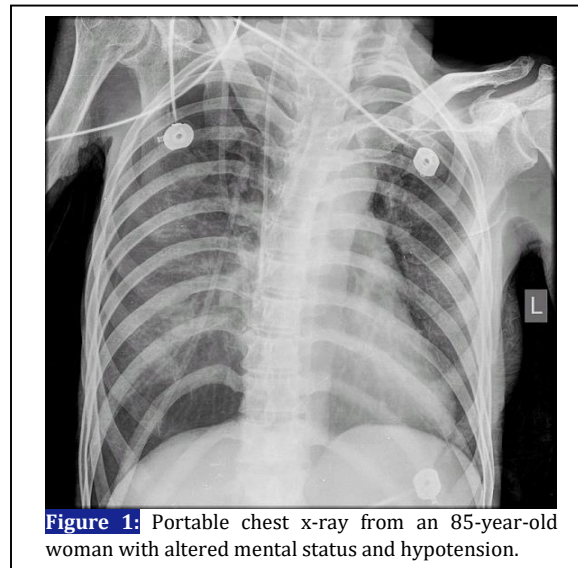


Figure 1: Portable chest x-ray from an 85-year-old woman with altered mental status and hypotension.

PATIENT'S HISTORY:

An 85-year-old female patient was brought to emergency department (ED) from a nursing home with altered mental status (GCS: 12/15) and hypotension (90/60 mmHg). Bilateral fine crackles in lungs and severe cachexia were obvious in her physical examination. The ECG showed only sinus tachycardia. Several attempts at peripheral vein cannulation failed due to poor visualization of severely atrophied and contracted subcutaneous veins. Therefore, on two attempts, a central venous catheter (CVC) was inserted into the right internal jugular vein (IJV) using the Seldinger technique. After securing and taping the central line, fluid infusion started with no difficulty and a portable chest x-ray was ordered (Figure 1).

KEY QUESTIONS:

- What are the radiologic findings in Figure 1?
- What is the importance of these findings?
- What other diagnostic modalities can be used for further assessment of this complication?

LEARNING POINTS:**Radiologic findings**

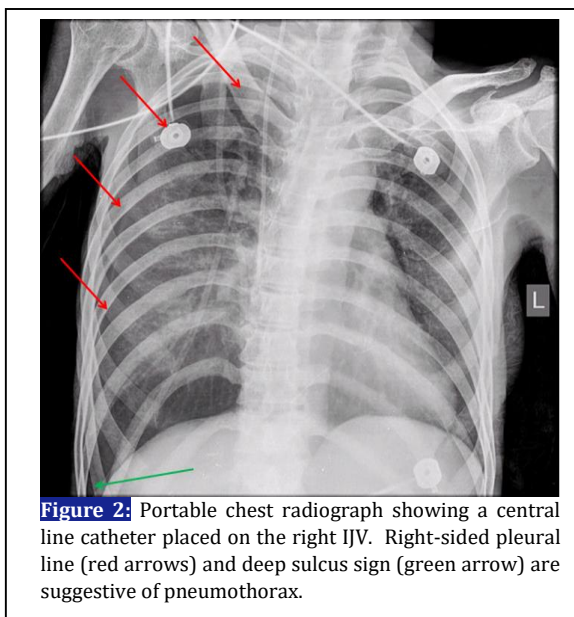
- The spinous process is close to the right clavicle

and the left lung is 'blacker' than the right due to the rotation of the patient to the left.

- The tip of the CVC is above the right atrium. It is recommended to place tip of CVC at the level of mid-lower superior vena cava (SVC) to cavoatrial junction, ideally outside the pericardial sac and parallel with the long axis of SVC (1, 4). Because the shadow of the right border of SVC cannot be seen clearly due to rotation, it is hard to confirm the correct position of the catheter inside SVC.
- The pleural line is visible on the right as a fine linear density (red arrows in Figure 2). The increase in brightness of right hemi-thorax (due to rotation and subcutaneous tissue) may obscure this line and it can be easily overlooked if the image is not observed carefully. As in this case, the emergency physician initially read the image as showing the catheter "adequately positioned" without any complication.
- A deep, lucent, costophrenic angle on the right is an indirect indicator of pneumothorax. As pleural air collects laterally and anteriorly in a supine patient (as opposed to the lung apex in an upright patient), the costophrenic angle is abnormally deepened and is therefore called "deep sulcus sign" (green arrow in Figure 2).
- Some degree of spinal scoliosis can be easily seen, as well.
- Cardiothoracic ratio cannot be assessed carefully due to rotation.

Importance

If not diagnosed immediately and managed properly, a simple pneumothorax may become tension pneumothorax after initiation of positive pressure ventilation (PPV). Then a tension pneumothorax can exacerbate initial hypotension due to impaired venous return and cause pulseless electrical activity (PEA) and cardiac arrest. In this scenario, blood pressure of the patient did not change after the initial bolus of infusion fluid and managing the patient's airway and breathing. So the emergency physician decided to repeat IV fluid and perform a non-contrast chest and brain spiral CT scan for further assessment of the patient. Needle or chest tube was not inserted because



pneumothorax was not recognized by the physician.

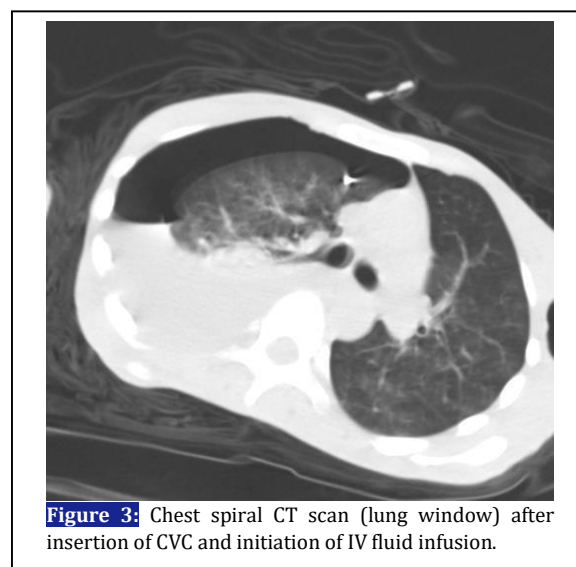
Diagnosis

Figure 3 shows the non-contrast chest spiral CT scan of the patient. A large pneumothorax and pleural effusion are seen in the right hemi-thorax. Increased haziness in the right lung may be a parenchymal disease (like pneumonia) or due to lung collapse or both. There is some degree of mediastinal shift to the left due to large pneumothorax and pleural effusion on the right. Recognizing these abnormalities in a hypotensive patient was enough for the emergency physician to insert a chest tube into the right hemi-thorax. Suddenly, approximately 1.5 liters of clear fluid came out. At this time, the physician suspected of malpositioned catheter and reevaluated the image and recognized it. CVC was obviously out of SVC and all of these findings clearly indicated malposition of the catheter. Because the physician did not expect a malpositioned catheter, they observed only a large pneumothorax and pleural effusion and did not recognize malpositioned CVC (you only see what your eyes want to see) and continued infusion of IV fluid before chest tube insertion. The catheter had actually been inserted into the right pleural space and caused pleural effusion with the infused IV fluid. Fluid infusion stopped immediately and the catheter was removed successfully with no complications after consultation with an interventional radiologist. Chest pain, dyspnea or back pain have been documented with infusion of IV fluids into the pleural space (1). A lack of resistance to infusion or

free return of venous blood does not guarantee appropriate CVC placement within a large vessel (2). Because this patient suffered a decreased level of consciousness, CVC malpositioning led to no signs or symptoms except agitation and restlessness.

Other useful diagnostic modalities

Anterior-posterior portable chest radiography is an important available diagnostic tool with a high diagnostic accuracy used for recognizing malpositioned catheter, but these 2D images have limitations. For instance, correct interpretation of these images requires knowledge of the normal anatomy and variations of mediastinal vessels related to CVC (2). Furthermore, distal section of the catheter may not be seen easily due to anatomical proximity of vessels to mediastinal structures and technical problems like rotation, so confirming the intended CVC location may not be possible (2). Other imaging techniques used for diagnosing malpositioned CVC include: Lateral chest radiograph; Injecting a small amount of contrast material through the catheter during conventional radiography or performing CT scan; Real-time radiograph imaging with an image intensifier and guiding wires and catheters centrally during CVC placement without injecting contrast; Transesophageal ultrasound to directly image the SVC (its practical limitation is operator's training and availability for confirming catheter tip position in the SVC); Injecting 10mL of agitated normal saline via the CVC port and ultrasonographic visualization of bubbles (seen as opacification) in the right atrium by transthoracic echo; CT scan or magnetic resonance imaging (2-4).



REFERENCES

1. Wang L, Liu ZS, Wang CA. Malposition of Central Venous Catheter: Presentation and Management. *Chin Med J* 2016;129:227-34.
2. Roldan CJ, Paniagua L. Central Venous Catheter Intravascular Malpositioning: Causes, Prevention, Diagnosis, and Correction. *West J Emerg Med*. 2015;16(5):658–664.
3. Horowitz R, Gossett JG, Bailitz J, et al. The FLUSH study--flush the line and ultrasound the heart: ultrasonographic confirmation of central femoral venous line placement. *Ann Emerg Med*. 2014;63(6):678-83.
4. Gibson F, Bodenham A. Misplaced central venous catheters: applied anatomy and practical management. *Br J Anaesth*. 2013;110(3):333-46.