

Case based learning points

DOI: 10.22114/ajem.v0i0.113

A Case of Cerebral Venous Sinus Thrombosis Presenting with Delirium

Mahnaz Pejman-Sani, Mahbube Ebrahimpur*

Department of Internal Medicine, Shariati Hospital, Tehran University of Medical Sciences, Tehran, Iran.

*Corresponding author: Mahbube Ebrahimpur; Email: m-ebrahimpur@tums.ac.ir

Published online: 2018-10-01

Cite this article as: Pejman-Sani M, Ebrahimpur M. A Case of Cerebral Venous-Sinus Thrombosis Presenting with Delirium. Adv J Emerg Med. 2019;3(1): e11.

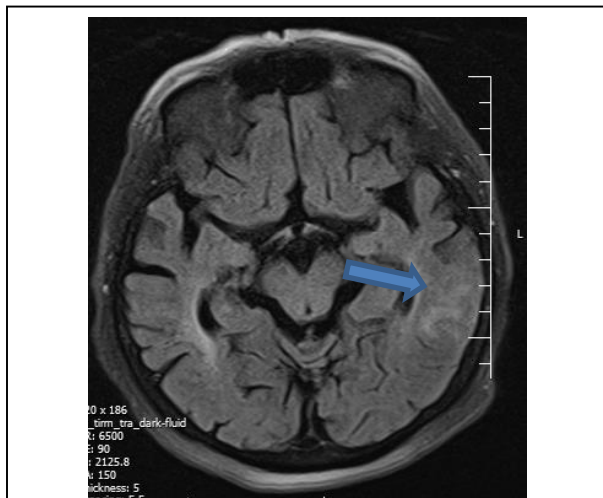


Figure 1: Brain MRI showing abnormal cortical and subcortical hyper-intense signal in the left temporal lobe with the foci of hyper-intense signal suggesting hemorrhagic venous infarction

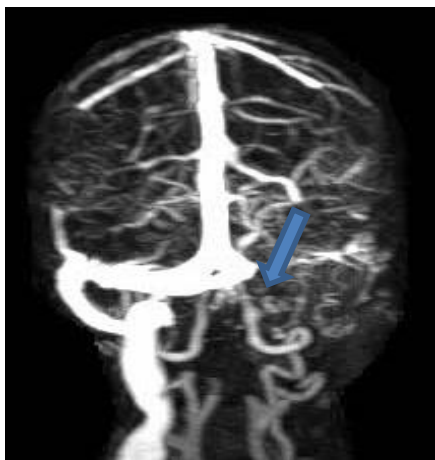


Figure 2: Left transverse sinus, jugular bulb and internal jugular vein (thrombosis) were not observed in MRV image

CASE PRESENTATION

A 73-year-old woman with no history of headache, seizure and trauma was admitted to the emergency department complaining about fever, vomiting and

delirium for 3 days. She was lethargic upon admission and her blood pressure (BP) was recorded as 140/90 mm/Hg, her pulse rate (PR) as 75 beat/min and oral temperature as 38 °C. No localizing findings were observed in neurological examinations. Laboratory findings were as follows: White Blood Cell (WBC) count: 7,000/mm³, Hemoglobin: 13 g/dl, Platelet count: 300000. Lumbar CSF, blood and urine cultures were found to be negative for infections. Brain Computed Tomography (CT) and Magnetic Resonance Imaging (MRI) were also performed. MRI showed filling defects in the left transverse sinus, the jugular bulb and the internal jugular vein. Moreover, hyper-intense signal was observed in the left temporal lobe (T1 sequence) suggesting hemorrhagic venous infarction (Figure1). The obtained results were confirmed by Magnetic Resonance Venography (MRV) of the brain (Figure2). The patient underwent anticoagulation therapy using LMWH and she was hydrated using physiologic solution. The patient's symptoms disappeared and she was then followed up regularly.

LEARNING POINTS

Cerebral Venous-Sinus Thrombosis (CVST) is a life threatening disease that accounts for only 0.5-1% of all strokes. CVTS occurs at all ages and its prevalence is estimated at about five per million of general population (1-3). The clinical manifestations of CVST may be acute, sub-acute or chronic based on the location and extension of thrombosis including headache, vomiting, altered mental status and seizure (4). The major predisposing factors comprise pregnancy, oral contraceptive pill (OCP) use, coagulopathies, intracranial infections, dehydration, malignancy, and inflammatory bowel disease and etiology is unknown in about 30% of patients (3, 5). Brain imaging plays a key role in diagnosing CVST owing to its nonspecific symptoms of the disease. CT

angiogram and MR angiogram with venography are highly sensitive and specific in diagnosing CVST (5). In the acute phase of CVST, heparin or LMWH are recommended followed by the oral anticoagulation for about 6-12 months (5). The mortality rate of CVST is 6%-10%. Loss of

consciousness is associated with higher mortality rates. CVST can therefore be associated with delirium in older adults and the treatment should not be postponed.

REFERENCES

1. Murthy KK, Chefitz DL. Cerebral venous sinus thrombosis: A case report with review of diagnosis and treatment strategies. *J Clin Case Rep.* 2014; 4: 354.
2. Soydinc HE, Ozler A, Evsen MS, Sak ME, Turgut A, Basaranoglu S, et al. A case of cerebral sinus venous thrombosis resulting in mortality in severe preeclamptic pregnant woman. *Case Rep Obstet Gynecol.* 2013;2013:402601.
3. Baratloo A, Safari S, Rouhipour A, Hashemi B, Rahmati F, Motamedi M, et al. The Risk of Venous Thromboembolism with Different Generation of Oral Contraceptives; a Systematic Review and Meta-Analysis. *Emergency.* 2014;2(1):1-11.
4. Hundozi Z, Ibishi N, Jashari F, Rrustemi J, Gjokolli B. Superior Sagittal Sinus Thrombosis Presenting with Hallucinations in the Puerperium; A Case Report. *Int J Biomed.* 2016;6(4):294-7.
5. Albright KC, Freeman WD, Kruse BT. Cerebral venous thrombosis. *J Emerg Med.* 2010;38(2):238-9.