

CASE REPORT

DOI: <https://doi.org/10.18502/fem.v6i4.10443>

Herpes simplex encephalitis after receiving COVID-19 vaccine; A case report

Zahra Ebadi, Fereshteh Ghadiri, Elnaz Asadollahzade, Abdorreza Naser Moghadasi*

Multiple Sclerosis Research Center, Neuroscience Institute, Tehran University of Medical Sciences, Tehran, Iran.

*Primary corresponding author: Abdorreza Naser Moghadasi; Email: abdorrezamoghadasi@gmail.com.

Published online: 2022-06-28

Abstract: Shortly after the onset of the coronavirus pandemic, different vaccines were developed to combat it. The vaccines had different mechanisms and triggered cellular and humoral immune responses against the virus. In addition to their positive effects, various side effects have been reported for them. They rarely cause severe complications. They can also rarely trigger latent infections. The present case report presents a patient who developed herpes simplex encephalitis after receiving the second dose of the Covaxin (BBV152).

Keywords: Adverse Effects; BBV152 COVID-19 Vaccine; COVID-19; COVID-19 Vaccines; Encephalitis; Herpes Simplex; Vaccination

Cite this article as: Ebadi Z, Ghadiri F, Asadollahzade E, Naser Moghadasi A. Herpes simplex encephalitis after receiving COVID-19 vaccine; A case report. *Front Emerg Med.* 2022;6(4):e56.

1. Introduction

COVID-19 has affected the whole world in the last two years and accounts for the death of many people. The development of vaccines creates hope for the end of this pandemic. Now, various types of vaccines are available such as viral vector-based vaccines, mRNA-based vaccines, inactivated or attenuated virus vaccines, as well as protein-based vaccines. With the increasing rate of vaccine injection, their side effects are also determined (1). One of the problems that can occur after receiving vaccines due to changes in the immune system is the risk of infection. There are some reports in this regard (2). The present case report presents a young man who developed herpes simplex encephalitis (HSE) shortly after receiving the Covaxin. Covaxin (BBV152) is an inactivated vaccine, developed and manufactured by Bharat Biotech in collaboration with the Indian Council of Medical Research (ICMR) and the National Institute of Virology (NIV) (3).

2. Case report

The patient, a 30-year-old healthy man, with a negative past medical history, developed headache, fever, nausea, and vomiting one day after receiving the second dose of the Bharat (Covaxin) vaccine. Following the decrease in his consciousness, he was referred to our center the next day. In the emergency room, he was confused with fever. He had no history of being on any medication. In neurological examination, he had left hemiparesis and ophthalmoparesis due to inability in right adduction. Brain magnetic resonance imaging (MRI) showed hyper signal lesions in both mesial temporal lobes, both insula, orbitofrontal lobe, and right thalamus with restriction and without enhancement (Figure 1). Lumbar puncture (LP) showed pleocytosis (white blood cell count (WBC): 30×10^3 with 80% lymphocyte dominancy, pro-

tein: 98 mg/dl, glucose: 40 mg/dl). After cerebrospinal fluid (CSF) analysis, acyclovir was started. HSV1 and 2 polymerase chain reaction (PCR) tests were requested. Moreover, since the patient had developed symptoms shortly after the vaccination and autoimmune encephalitis was one of the suspected diagnoses, intravenous immunoglobulin (IVIG) was started. The autoimmune panel in both CSF and serum was negative. Over the course of the disease, the patient's consciousness deteriorated and he was intubated. Surprisingly, the HSV PCR result was positive, thus treatment with acyclovir was continued for 21 days. Finally, the patient's consciousness improved.

3. Discussion

Herpes virus is one of the most common viruses, accounting for 52 to 84% of the infections among the adult population (4). It is most often hidden in the trigeminal ganglia (5) and becomes symptomatic in special conditions such as fever or stress. One of the rare presentations of this virus is HSE (5). Activation of latent viruses after vaccination has rarely been reported. In Taiwan, three cases of cutaneous herpes zoster have been reported shortly after receiving the COVID-19 vaccine (Moderna & AstraZenca) (2). The exact mechanism of viral encephalitis after vaccination is not determined yet. There are several hypotheses in this regard, including a post-vaccination complication due to molecular similarity. Another hypothesis is the confusion of immune system after the initial local response at the site of vaccine injection providing the chance for the hidden virus to activate. Besides, after vaccination, cytokines are released inducing latent viruses such as HSV (5). To the best of our knowledge, this case report is the second one in the literature reporting the development of herpes simplex encephalitis after receiving

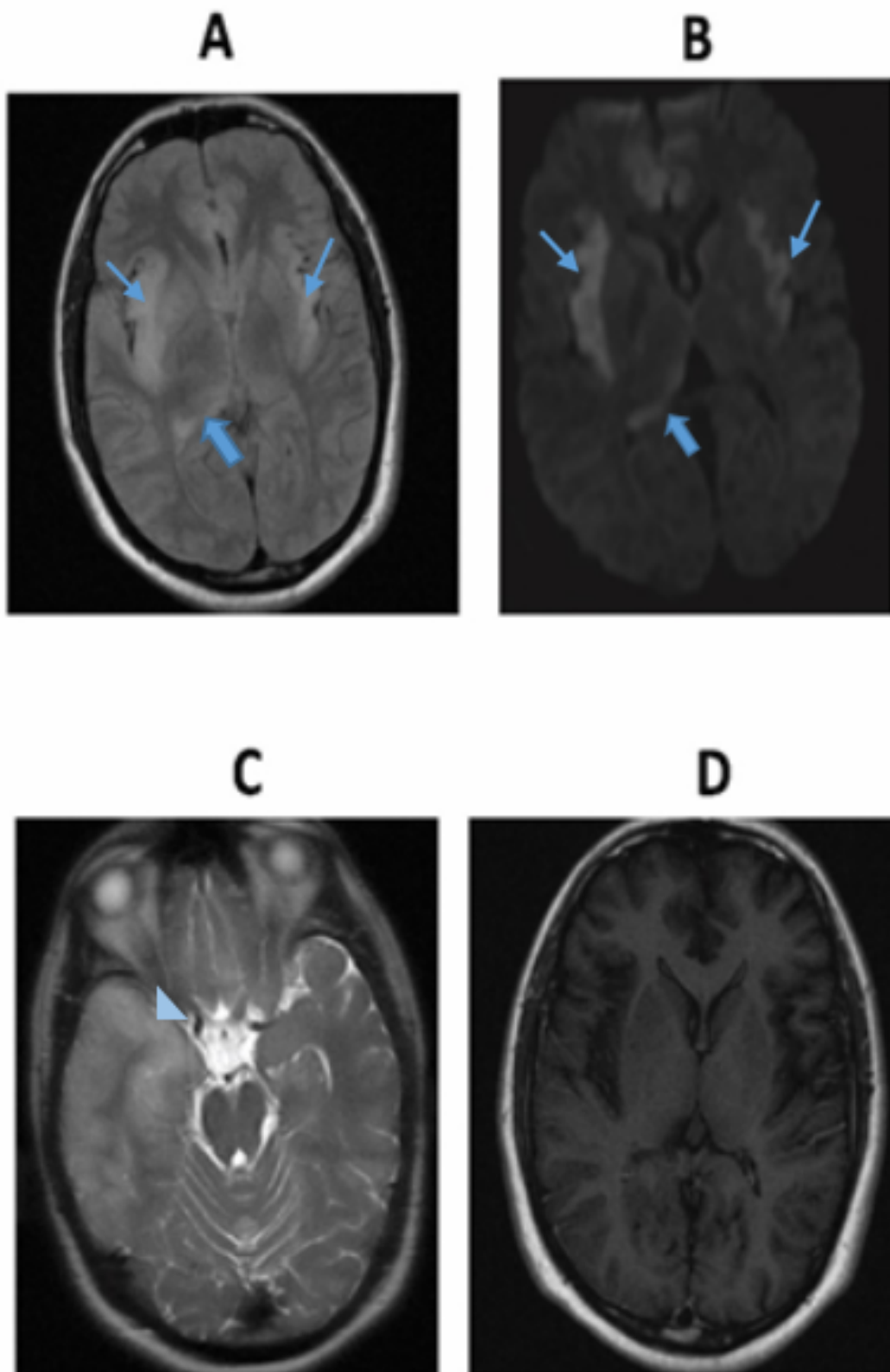


Figure 1 A) Inversion recovery magnetic resonance imaging (FLAIR MRI) showed hypersignal lesions in both insula (thin arrows) and the right thalamus (thick arrow); B) Diffusion-weighted MRI (DWI) showed restriction; C) T2 weighted image: hypersignal lesion in right temporal lobe (arrowhead); D) T1-weighted MRI with contrast: no gadolinium enhancement

ing the COVID-19 vaccine. The first case was reported by Moslemi et al. (5), a 27-year-old man complicated with HSE after receiving the ChAdOx1 nCoV-19 vaccine. However, it must be acknowledged that serious side effects of the COVID-19 vaccine are rare (6) and the vaccine injections are recommended to be continued to control the pandemic.

4. Conclusion

This rare case of herpes simplex encephalitis after vaccination against COVID-19 points to the possible underlying immune dysregulation early after vaccination.

5. Declarations

5.1. Acknowledgment

None.

5.2. Authors' contribution

All the authors met the standards of authorship based on the recommendations of the International Committee of Medical Journal Editors.

5.3. Conflict of Interest

All authors declare that they have no conflict of interest.

5.4. Funding

None.

5.5. Consent for publication

The patient's guardian agreed to the publication of the report under the condition that the patient's identity is not revealed.

References

1. Garg RK, Paliwal VK. Spectrum of neurological complications following COVID-19 vaccination. *Neurol Sci.* 2022;43(1):3–40.
2. Chiu HH, Wei KC, Chen A, Wang WH. Herpes zoster following COVID-19 vaccine: a report of three cases. *QJM.* 2021;114(7):531–2.
3. Sharun K, Dhama K. India's role in COVID-19 vaccine diplomacy. *J Travel Med.* 2021;28(7):taab064.
4. Pebody R, Andrews N, Brown D, Gopal R, de Melker H, Francois G, et al. The seroepidemiology of herpes simplex virus type 1 and 2 in Europe. *Sex Transm Infect.* 2004;80(3):185–91.
5. Moslemi M, Ardalan M, Haramshahi M, Mirzaei H, Sani SK, Dastgir R, et al. Herpes simplex encephalitis following ChAdOx1 nCoV-19 vaccination: a case report and review of the literature. *BMC Infect Dis.* 2022;22:217.
6. Rabail R, Ahmed W, Ilyas M, Rajoka MSR, Hassoun A, Khalid AR, et al. The Side Effects and Adverse Clinical Cases Reported after COVID-19 Immunization. *Vaccines (Basel).* 2022;10(4):488.