

CASE BASED LEARNING POINTS

DOI: <https://doi.org/10.18502/fem.v6i4.10445>

Abdominal pain with oral pigmentations as a clue for Peutz-Jeghers syndrome

Mohammad Ebrahim Kalantari¹, Hossein Savadi¹, Hamzeh Sherafati¹, Ali Akbar Bagherzadeh², Tooraj Zandbaf^{3*}

1 Surgical Oncology Research Center, Mashhad University of Medical Sciences, Mashhad, Iran.

2 Innovative Medical Research Center, Faculty of Medicine, Mashhad Medical Sciences, Islamic Azad University, Mashhad, Iran.

3 Department of General Surgery, Faculty of Medicine, Mashhad Medical Sciences, Islamic Azad University, Mashhad, Iran.

*Corresponding Author: Tooraj Zandbaf; Email: tooraj.zandbaf@gmail.com

Published online: 2022-05-12

Cite this article as: Kalantari ME, Savadi H, Sherafati H, Bagherzadeh AA, Zandbaf T. Abdominal pain with oral pigmentations as a clue for Peutz-Jeghers syndrome. *Front Emerg Med.* 2022;6(4):e58.

1. Case presentation

A 33-year-old woman presented to the emergency department with colicky abdominal pain, nausea and vomiting, constipation, obstipation, and rectorrhagia. She had a history of similar abdominal pain from a few months ago. She had no history of any specific disease and taking any medication. She had no history of surgery and specific family diseases. Her vital signs on admission were heart rate 90/minute, respiratory rate 18/minute, blood pressure 110/70 mmHg, and temperature of 37.1°C. There were several brown spots on her lips and inside her mouth. On abdominal examination, she had a generalized tenderness, especially in the LLQ. In the digital rectal examination, the rectum was empty. Lab tests showed the following results: leukocyte count 4000/mm³ with 80.9% neutrophils, hemoglobin 12.1 g/dl, platelet 320000/μl, and creatinine 0.6 mg/dl, BUN 14 mg/dl, glucose 152 mg/dl, sodium 137 mEq/L, potassium 4.5 mEq/L. Chest and abdominal radiographs were performed on the patient (Figure 1). No subdiaphragmatic free air was seen in the chest x-ray. The abdominal x-ray showed no air-fluid levels as well as any gas in the rectum. On abdominal and pelvic ultrasound, a moderate amount of free fluid was seen in the abdomen along with jejunoileal intussusception in the LLQ with an intestinal loops thickness increase.

The patient was nominated for surgery with a diagnosis of intestinal obstruction due to intussusception. After laparotomy, it was found that the loops of the small intestine were very dilated due to jejunojejunal intussusception (Figure 2A). The intussusception segment was stretched and tried to turn to its normal state, and it was found that a segment about 20 cm from the jejunum had become gangrenous (Figure 2B). This segment was resected, and the two ends of the intestine were anastomosed together. On the examination of the small intestine by hand, multiple polyps were touched (Figure 3A). Also, there were multiple lymphadenopathies in the mesentery of the small intestine and a biopsy was performed (figure 3B). Seven days later, she was discharged from the hospital in good general condition. Histopathological ex-

amination of lymph node indicating reactive lymph node. Furthermore, examination of the small intestine indicated hemorrhagic necrosis and two hamartoma polyps suggesting Peutz-Jeghers.

2. Learning points

Peutz-Jeghers syndrome (PJS) is a rare autosomal dominant disorder characterized by oral hyperpigmentation, multiple gastrointestinal mucosal benign hamartomatous polyps causing local bleeding, obstruction, intussusception, small bowel syndrome, and small intestinal cancer. It also has a greater risk of having nongastrointestinal tumors than the general population including testicular, pancreatic, gynecologic, and breast cancers. The presence of gastrointestinal polyps is remarkably linked to the severity of the dermatological findings. It is said that the most serious and perhaps life-threatening manifestation of PJS is small bowel intussusception (1–4).

The presence of hamartomatous polyps is a specific feature of PJS in the digestive tract. The small intestine, colon, and stomach are the most common sites, despite the duodenum and appendix which are uncommon. The duodenum is the most common site of complicated polyps (1). A malignancy was diagnosed at an average age of 42 years. Colorectal cancer was shown to be the most common type of cancer, followed by breast, stomach, small intestines, and pancreas (4). The skin and mucosal lesions are important markers of the syndrome, assisting in the early detection of hamartomatous polyps and serial surveillance for the increased risk of breast, uterine, ovarian, and pancreatic neoplasia associated with the syndrome (1). Because PJS can lead to a variety of problems, early detection is essential to avoid surgical intervention. A colonoscopy, upper GI endoscopy, and extraintestinal tumors screening are among the current surveillance recommendations (4, 5).

Abdominal pain in a patient with oral pigmentations could indicate gastrointestinal PJS polyp complications. Lifelong

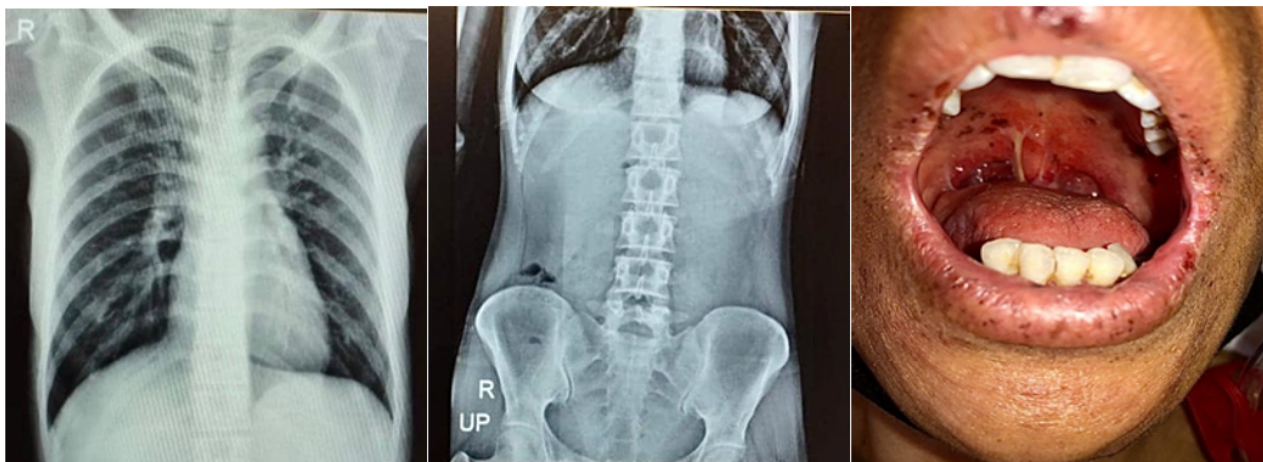


Figure 1 Upright chest X-Ray (left), upright abdominal X-Ray (middle), and patient's face (right)

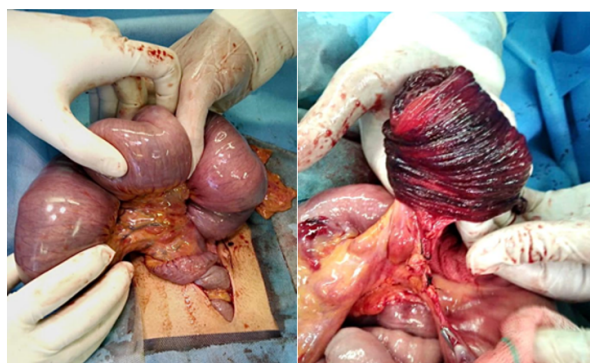


Figure 2 Jejunojunal intussusception (left); gangrenous segment of jejunum (right)

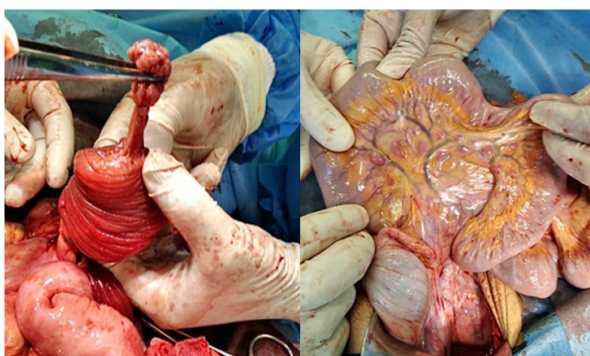


Figure 3 Hamartomatous polyp (left); mesenteric lymphadenopathies (right)

follow-up is essential. Because a gastrointestinal disease might be asymptomatic for years, a genetic consultation seems to be beneficial.

3. Declarations

3.1. Acknowledgement

The authors would like to express their profound gratitude to medical personnel involved in the treatment of this patient

in Imam Reza Hospital.

3.2. Authors' contribution

The authors meet the four criteria for authorship based on the recommendations of the International Committee of Medical Journal Editors (ICMJE).

3.3. Conflict of interest

None.

3.4. Funding

None.

3.5. Consent for publication

The patient's written consent was obtained for the publication of this article.

References

- Sandru F, Petca A, Dumitrascu MC, Petca RC, Carsote M. Peutz-Jeghers syndrome: Skin manifestations and endocrine anomalies. *Exp Ther Med*. 2021;22(6):1-7.
- Wagner A, Aretz S, Auranen A, Bruno MJ, Cavestro GM, Crosbie EJ, et al. The management of peutz-jeghers syndrome: European hereditary tumour group (ehtg) guideline. *J Clin Med*. 2021;10(3):1-18.
- Gorji L, Huish G, Morgan J, Levy P. A case of sporadic Peutz-Jeghers syndrome presenting as multiple intussusceptions. *J Surg Case Rep*. 2022;2022(3):rjac070.
- Sreemantula HS, Joseph CA, Jamal F, Agrawal S, Thirumarar R. Intussusception Caused by Peutz-Jeghers Syndrome. *Cureus*. 2022;14(4): e23792.
- Klimkowski S, Ibrahim M, Rovira JJI, Elshikh M, Javadi S, Klekers AR, et al. Peutz-jeghers syndrome and the role of imaging: Pathophysiology, diagnosis, and associated cancers. *Cancers (Basel)*. 2021;13(20):5121.